

Too fast, too slow, too ugly: Dangerous Dysrhythmias

Can your staff nurses recognize an abnormal cardiac rhythm and intervene appropriately?

By AnneMarie Palatnik, MSN, RN, APN-BC

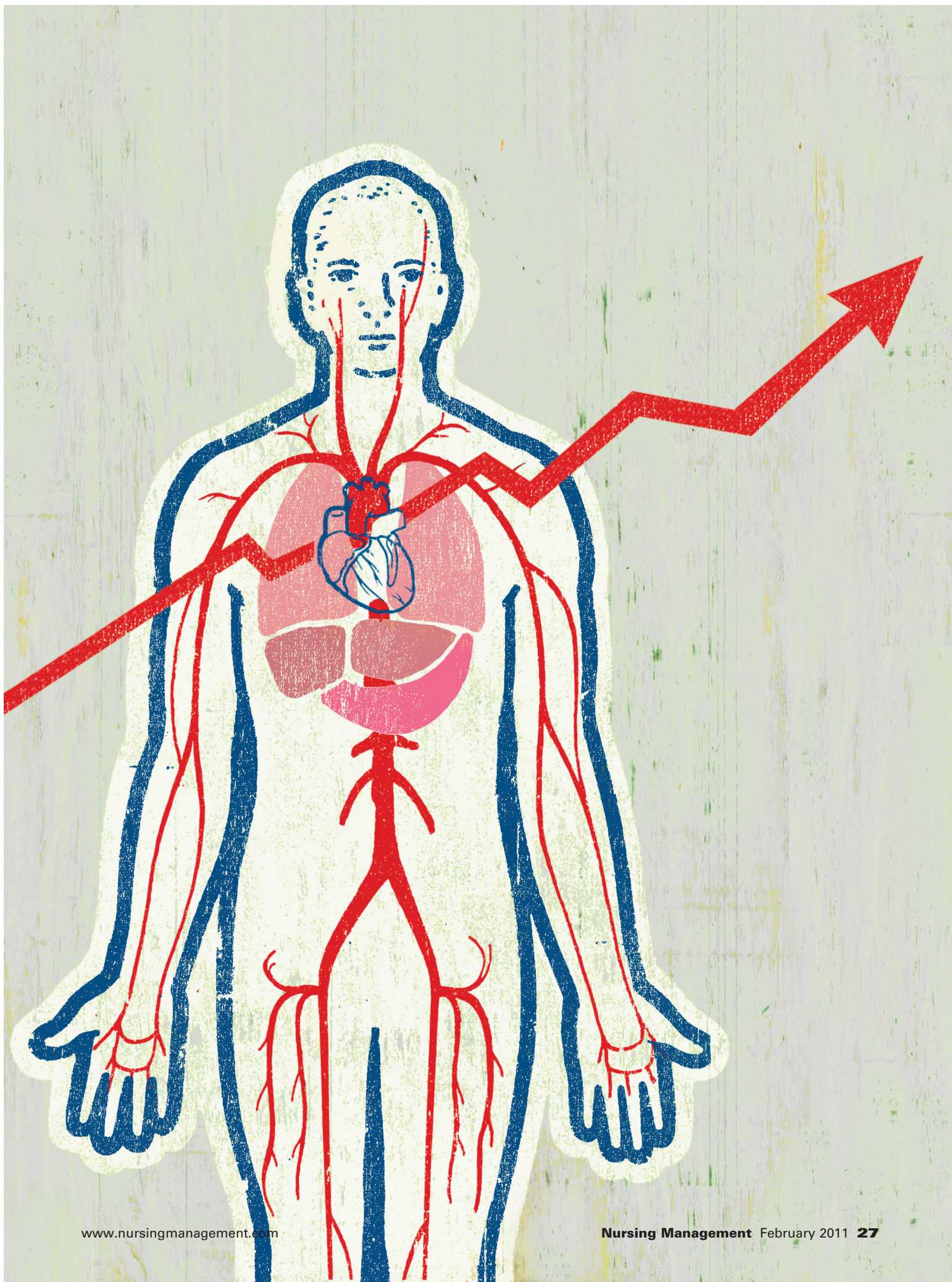
Continuous cardiac monitoring is used in many different clinical settings, so staff members need a basic knowledge of cardiac rhythms no matter where they work. In this article, I'll review normal cardiac anatomy and electrophysiology, then describe cardiac rhythms that are too fast or too slow, or just plain ugly. I'll also discuss treatments for each significant dysrhythmia.

When caring for a patient with a dysrhythmia, staff should treat the patient, not the monitor. They should assess and support the patient's airway, breathing, and circulation, and obtain vital signs including pulse oximetry. Also, they should administer supplemental oxygen as indicated, ensure patent I.V. access, obtain a 12-lead ECG, and notify the patient's healthcare provider.

Power and the pump

As you know, the atria act as blood reservoirs; about 70% of total cardiac output (CO) flows passively from the atria to the ventricles. The remaining 30% passes to the ventricles when the atria contract, known as *atrial kick*. In some atrial dysrhythmias, atrial kick is lost, which decreases CO and can cause hypotension. In addition, the blood that pools in the atria can form thrombi and travel to other parts of the body, including the brain, where a thrombus can cause a stroke.

The ventricles are two separate pumps. The right ventricle pumps blood into the pulmonary circulation

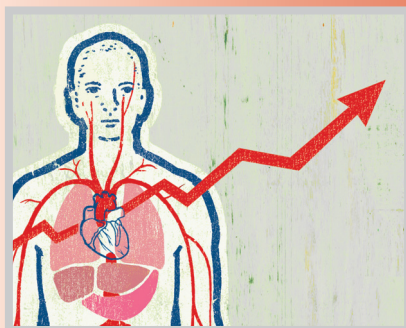


for oxygenation in the lungs, the left ventricle pumps the oxygenated blood into the systemic circulation for travel to the rest of the body.

The cardiac conduction system provides the power for the pumps.

electrical impulses, filaments in the cells shorten, causing mechanical contraction.

The pathway that the electrical impulse travels is called the heart's conduction system. (See *It's electric!*



In repolarization, which corresponds to diastole—the resting phase of the cardiac cycle—ions are again exchanged, “resetting” the heart electrically so it’s ready for the next depolarization and contraction.

Electrical impulses generated by the exchange of ions—primarily potassium, sodium, chloride, and calcium—cause depolarization (the electrical event) and myocardial contraction or systole (the mechanical event). In repolarization, which corresponds to diastole—the resting phase of the cardiac cycle—ions are again exchanged, “resetting” the heart electrically so it’s ready for the next depolarization and contraction.

Specialized myocardial cells called *pacemaker cells* spontaneously generate electrical impulses. Electrical conducting cells in the heart then pass these impulses to the next cell. As the cardiac cells conduct the

Understanding cardiac conduction.)

Normally, the impulse is initiated in the sinoatrial (SA) node, the heart’s natural pacemaker. The SA node is located at the junction of the right atrium and superior vena cava, just above the tricuspid valve, and normally generates 60 to 100 impulses/minute. Numerous other potential pacemakers can be found along the conduction system, and any one of these can take over as the heart’s pacemaker if the SA node fails to fire, or if it fires but the electrical impulses are too slow or blocked. For example, if the SA node fails to fire, the atrioventricular (AV) node can kick in and become the heart’s pace-

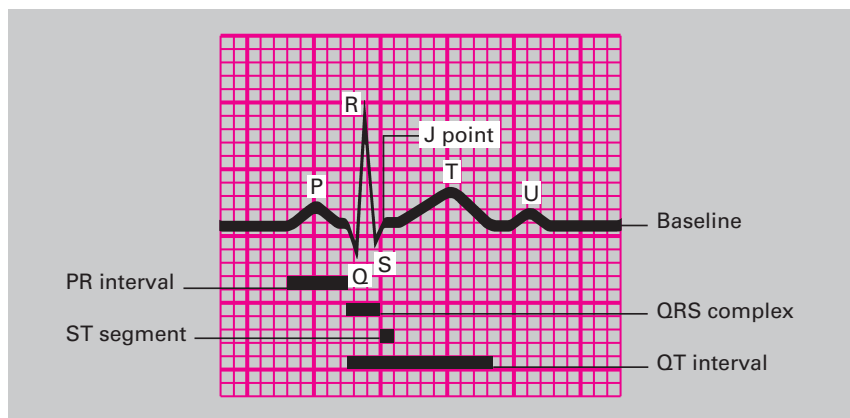
maker. However, the AV node generates only 40 to 60 impulses/minute. If both the SA and AV nodes fail to fire, or if the impulses are too slow or are blocked, the Purkinje fibers in the ventricles will kick in as the heart’s pacemaker, but at a much slower rate of (20 to 40 beats/minute).

A change in heart rate, whether too fast or too slow, can decrease the patient’s CO, which is determined by multiplying heart rate by stroke volume (the amount of blood pumped out of the left ventricle with each beat). For example, a heart rate greater than 100 beats/minute shortens diastolic filling time and can decrease CO in some patients.

Doing the wave

The heart’s electrical activity can be represented graphically on an ECG (see illustration below). As you know, one cardiac cycle normally consists of a P wave, a QRS complex, and a T wave, and the intervals and segments between these waves. Let’s take a closer look:

- The *P wave*, the first wave, represents atrial depolarization (the electrical impulse as it travels through the atria). The P wave should be positive in leads II, III, and aVF; positive, isoelectric, or biphasic in leads I and aVL; inverted in lead aVR; and biphasic in lead V1. You should see one P wave before every QRS complex.
- The *QRS complex* represents ventricular depolarization. The normal QRS duration is between 0.06 and 0.10 second.
- The *T wave*, which immediately follows the QRS complex, represents ventricular repolarization.
- The *PR interval*, measured from the beginning of the P wave to the beginning of the QRS complex, represents the time the impulse takes to travel from the SA node to the ventricles. A normal PR interval is 0.12 to 0.20 second.



- The *ST segment* is the straight line between the end of the QRS complex and the beginning of the T wave. This segment represents the time from the end of ventricular depolarization to the beginning of ventricular repolarization.

- The *QT interval*, which includes the QRS complex, the ST segment, and the T wave, represents the time from the beginning of ventricular depolarization to the end of ventricular repolarization. Because the QT interval varies with heart rate, a corrected QT interval (QTc) is calculated by dividing the QT interval by the square root of the R-R interval. Normal QTc intervals are less than 0.43 second in men and less than 0.45 second in women.

The grid on the ECG paper lets you measure waveform durations, intervals, and the height and depth of a wave. On the horizontal axis, which represents time, one small box equals 0.04 second and a large one (consisting of five small boxes) equals 0.20 second. The vertical axis measures amplitude or voltage. Each small box represents 1 mm (0.1 millivolt); each large box represents 5 mm (0.5 millivolt).

Analyzing the ECG rhythm

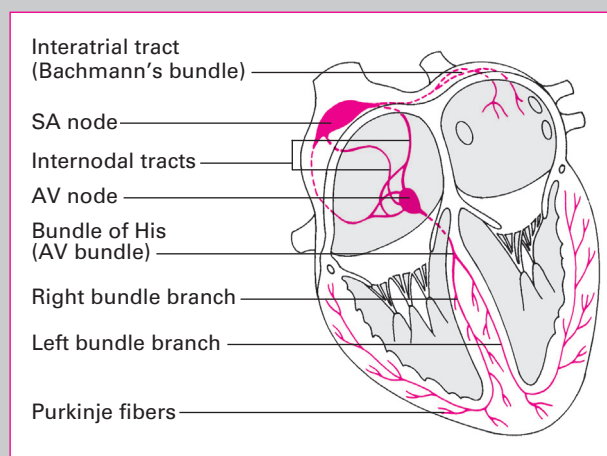
Your frame of reference is normal sinus rhythm: a heart rate between 60 and 100 beats/minute with regular atrial and ventricular rhythms and P waves that are uniform, round, and upright in most leads, and occur before each identical QRS complex. The PR interval and QRS duration will be normal.

Follow these steps when analyzing a rhythm strip:

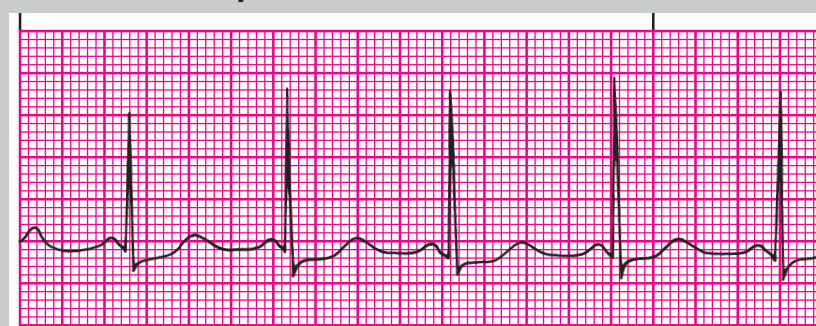- *Determine the rate.* You can make a quick estimation of the ventricular rate by counting the number of QRS complexes in a 6-second section and multiplying that number by 10. Count the number of P waves in a 6-second section and multiply

It's electric! Understanding cardiac conduction

Normal cardiac impulses originate in the SA node and travel through interatrial pathways to the AV node, the gatekeeper between the atria and the ventricles. The AV node instantaneously holds onto the impulse and allows the ventricles to fill with blood. The impulse then travels from the AV node through the bundle of His, branching off to the right and left bundle branches and the Purkinje fibers through to the myocardium, where mechanical contraction takes place.



Normal sinus rhythm



that number by 10 to determine the atrial rate.

A more accurate way to determine rate is to count the number of large boxes between QRS complexes for the ventricular rate (or the number of large boxes between P waves for the atrial rate) and divide 300 by this number. This method is especially helpful when you need to estimate the rate in short bursts of dysrhythmias.

- *Determine if the rhythm is regular or irregular.* Measure the distance from

one R wave to the next R wave (R-R interval). If the R-R intervals are consistent, the ventricular rhythm is regular. Next, measure the distance from one P wave to the next P wave (P-P interval). If the P-P intervals are consistent, the atrial rhythm is regular.

- *Evaluate the P waves.* Does one P wave appear before every QRS complex? Do all the P waves look normal (round and upright) and the same? If the P waves look abnormal, they could be originating from somewhere in the atria other

than the SA node. For example, if P waves are inverted, hidden in the QRS complex, or occur after the QRS complex, the impulse is most likely originating in the AV junction. An absence of P waves means atrial kick has been lost.

- *Evaluate the QRS complexes.* Do they all look the same? Do they have a typical configuration and normal duration? Does a QRS complex follow each P wave?

- *Look at the relationship between the P waves and the QRS complexes.* Does one P wave appear before every QRS, and are all of the PR intervals the same?

When a cardiac rate, rhythm, or both deviate from normal, your job is to determine the significance of this deviation. Compare the abnormal rate or rhythm to normal sinus rhythm—is it too fast, too slow, or too ugly?

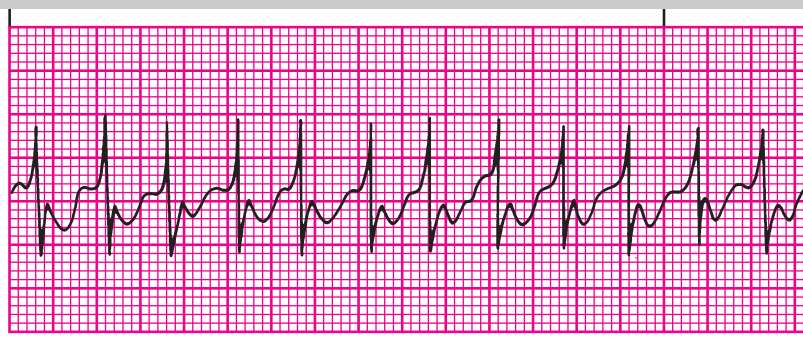
Too fast: Supraventricular tachycardia

Any resting heart rate greater than 100 beats/minute is too fast. But how fast is too fast? Normally, a rate between 100 and 150 beats/minute is a response to increased metabolic demand. For example, when a patient gets out of bed for the first time postoperatively, you can expect that his heart rate might go above 100 beats/minute, especially if he's not taking medications that slow the heart rate, such as beta-blockers. Once the patient is resting back in bed, his heart rate should return to normal.

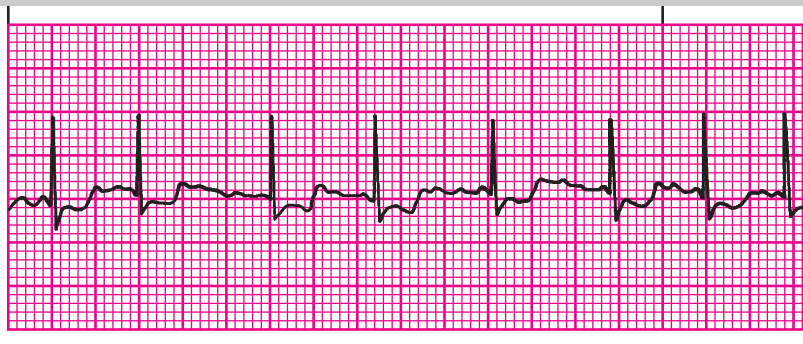Supraventricular tachycardia (SVT) is defined as a regular rhythm that originates above the ventricles and has a rate greater than 150 beats/minute. If your patient's heart rate is above 100 beats/minute, you need to determine if the impulse is coming from above the ventricles (supraventricular) or from the ventricles themselves. Here's how to tell:

If the origin of the impulse is supraventricular, conduction through the ventricles will be normal. On the ECG, you'll see a normal QRS with a normal duration. You may or may not see P waves. Because the heart is contracting so quickly, ventricular filling time decreases, and your patient will begin to exhibit signs and symptoms of decreased CO, such as confusion; diaphoresis; dyspnea; hypotension; near-syncope; syncope; pale, cool extremities; and oliguria. If he's hemodynamically stable (that is, he has no serious signs and symptoms related to the dysrhythmia), have him perform a simple vagal maneuver such as coughing, which may break the dysrhythmia. If vagal maneuvers don't work, the prescriber may order adenosine, which usually terminates SVT. Because of its very short half-life, give adenosine by rapid I.V. push. Adverse

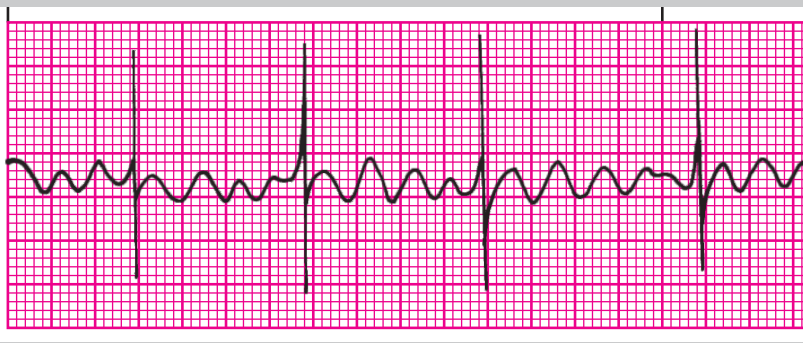SVT



Uncontrolled AF



Atrial flutter



reactions include transient flushing, chest discomfort, brief periods of asystole or bradycardia, and ventricular ectopy. Place the patient supine before administering the drug and record a rhythm strip during administration.

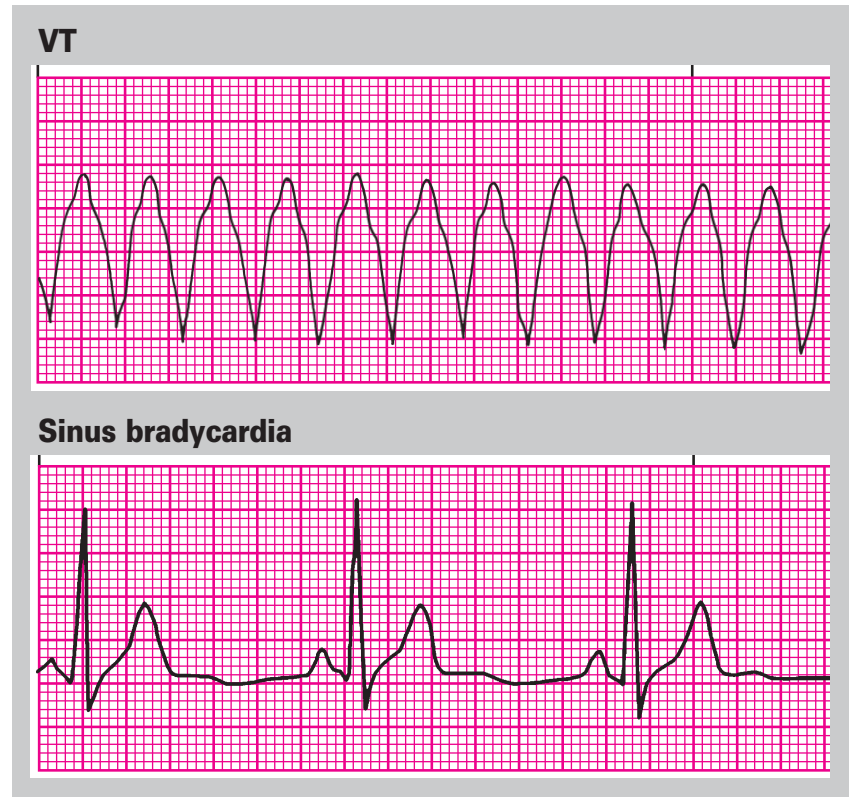
If the SVT doesn't convert with I.V. adenosine administered according to advanced cardiac life support (ACLS) guidelines, the rapid rate may be controlled with I.V. diltiazem or a beta-adrenergic blocker such as metoprolol. If the patient experiences serious signs and symptoms related to the tachycardia (150 beats/minute or greater) associated with a pulse, prepare to assist with immediate synchronized electrical cardioversion.

Too fast and too ugly: Uncontrolled AF and VT

A fast, ugly irregular rhythm is most likely to be *uncontrolled atrial fibrillation* (AF) in which the impulse is generated by multiple sites within the atria. In this case, you won't see discrete P waves on the ECG. Remember that this rhythm isn't always fast, just irregular with no identifiable P waves and a generally normal QRS complex.

Based on current evidence-based guidelines, anticoagulation should always be considered for a patient with AF, but is beyond the scope of this article. Rapid AF is often treated with diltiazem to control the ventricular rate. Diltiazem slows conduction through the AV node, slows the ventricular response, and gives the SA node a chance to resume its role as the normal pacemaker.

Remember that diltiazem is a calcium channel blocker that causes peripheral vasodilation, so it can worsen the hypotension that may be associated with AF. Monitor the patient's BP closely and intervene as indicated. If the patient is hemodynamically unstable with serious



signs and symptoms related to the rapid ventricular rate (greater than 150 beats/minute), he'll most likely need synchronized electrical cardioversion.

Atrial flutter is sometimes confused with AF. In both rhythms, P waves are lost. However, in atrial flutter you'll see sawtooth-like flutter waves at regular intervals. The rhythm may be regular or irregular, and the rate may be controlled at less than 100 beats/minute or uncontrolled at more than 100 beats/minute. This causes the atria to quiver and effective atrial contraction, as well as atrial kick, is lost. Because of this loss of atrial kick, CO is reduced by about 30%, increasing the patient's risk of thrombus formation. Treatment strategies are similar to those for AF.

Ventricular tachycardia (VT), another rhythm that's too fast and too ugly, occurs when the ventricles take over as the heart's pacemaker. The most common cause of VT is

coronary artery disease. Other causes of VT include serum electrolyte imbalances, myocardial ischemia and infarction, and hypoxemia. You can easily spot rhythms originating in the ventricles by their wide (greater than 0.12 second) and bizarre QRS complexes on the ECG. Typically, VT has a rate of at least 150 beats/minute and is regular. P waves usually are absent; if they occur, they'll have no consistent relationship to the QRS complexes. This is called AV dissociation. Some patients with VT have a palpable pulse and may be completely asymptomatic, at least initially; other patients are unresponsive, apneic, and pulseless, requiring CPR and ACLS.

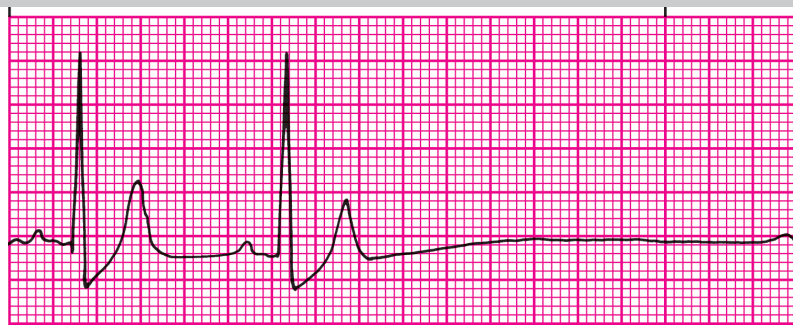Patient management depends on the patient's clinical status. If the patient has pulseless VT, treat the rhythm as you would ventricular fibrillation (VF). Call a code, start CPR, defibrillate the patient as quickly as possible, and provide

other interventions according to ACLS guidelines. If the patient is hemodynamically unstable but has

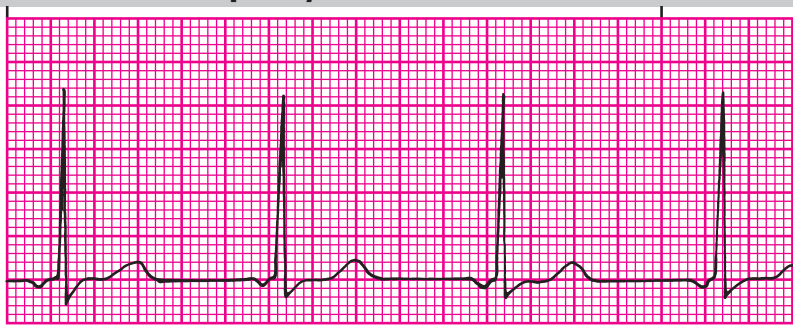a pulse, perform immediate synchronized electrical cardioversion. If the patient is hemodynamically

stable, administer amiodarone as prescribed and prepare for elective synchronized cardioversion according to ACLS guidelines.

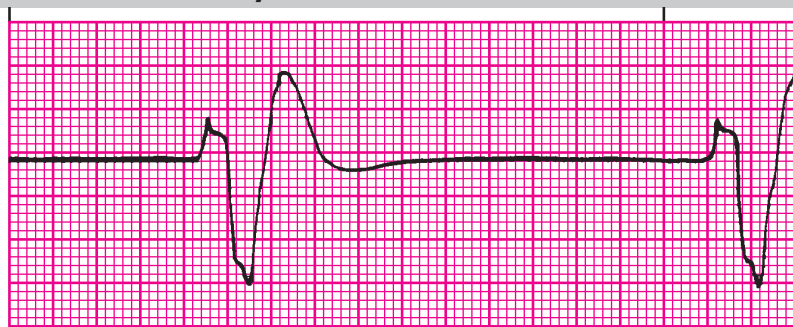
Pauses



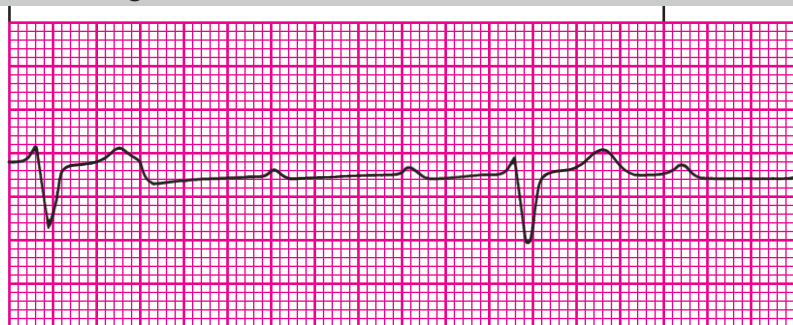
Junctional escape rhythm



Idioventricular rhythm



Third-degree AV block



Too slow: Sinus bradycardia

The most common slow rhythm is *sinus bradycardia*, which is a sinus rhythm with a heart rate of less than 60 beats/minute. Causes include increased vagal tone associated with myocardial infarction, adverse drug reactions, electrolyte imbalances, hypoxemia, hypoglycemia, hypothyroidism, and increased intracranial pressure.

A low heart rate generally means a low CO, but the significance of sinus bradycardia depends on the patient's clinical status. For example, if his daytime heart rate of 64 beats/minute drops to 56 beats/minute when he's sleeping, he isn't likely to be symptomatic with this bradycardia or require treatment. However, if a patient arrives in the ED after a syncopal episode with heart rate of 40 beats/minute and other signs and symptoms of poor perfusion, he requires immediate treatment following ACLS guidelines. Signs and symptoms of poor perfusion include acute change in mental status, hypotension, ongoing chest discomfort, near-syncope, and syncope.

For symptomatic bradycardia, the drug of choice is I.V. atropine, administered while the patient is being prepared for transcutaneous pacing. Atropine makes the SA node fire faster and speeds impulse conduction through the AV node.

Because atropine increases myocardial oxygen demand, it should be used cautiously in patients with myocardial ischemia. An epinephrine or dopamine infusion can be considered while waiting for transcutaneous pacing or if transcutaneous pacing is ineffective.

Keep in mind that patients who've had a heart transplant won't respond

to atropine, because the transplanted heart lacks vagal innervation. For them, transcutaneous pacing is the treatment of choice.

Transcutaneous pacing is also a first-line intervention for symptomatic bradycardia, and should be started immediately for patients who are unstable, particularly those with high-degree heart block (Mobitz type II second-degree or third-degree). Some limitations apply. Transcutaneous pacing can be painful for the patient and may not produce effective mechanical capture.

Noninvasive transcutaneous pacing can be performed at the bedside, and should be started immediately if the patient doesn't respond to atropine, if atropine is unlikely to be effective, or if the patient is severely symptomatic.

After pacing has been established, verify mechanical capture and reassess the patient's condition. Administer analgesia and sedation as ordered, and consult the cardiologist. If mechanical capture is inconsistent, prepare the patient for transvenous pacing.

Too slow and too ugly: Pauses, junctional, and idioventricular rhythms

A rhythm with *pauses* (missing P, QRS, and T waves on ECG) is too slow and too ugly. Again, the significance of this dysrhythmia depends on the patient's clinical status. Does he have signs or symptoms of poor perfusion caused by the bradycardia? How long are the pauses and how often do they occur? Possible causes and patient management are the same as for bradycardia.

Junctional escape rhythm occurs when the SA node fails to fire, the electrical impulse from the SA node is slower than that of the AV node, or the impulse from the SA node is blocked. The AV junction takes over as pacemaker, but because the

AV junction generates only 40 to 60 impulses/minute, junctional rhythms may be too slow. They're also too ugly: Because the impulse is initiated in the AV junction, it can travel retrograde through the atria, resulting in a P wave that's inverted, hidden, or occurs after the QRS complex. The QRS complex will usually appear normal because the impulse travels normally through the ventricles. Management of junctional escape rhythm is the same as for bradycardia.

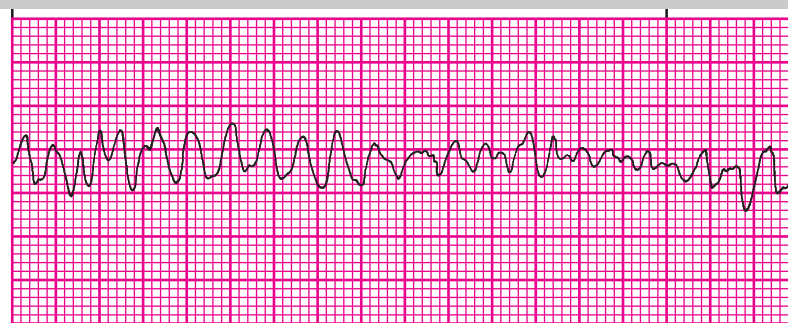
Idioventricular rhythm with a rate below 50 beats/minute is also too slow and too ugly. This rhythm occurs when the SA and AV nodes fail to fire, or the impulses are blocked, leaving the cells of the His-Purkinje system in the ventricles to generate their own impulses. However, the ventricles can generate a rate of only 20 to 40 beats/minute. The resulting rhythm is usually regular, but you'll see wide and bizarre QRS complexes and no P waves because

the atria aren't depolarized. T waves are generally inverted because of abnormal ventricular repolarization. CO falls because of the low heart rate and loss of atrial kick. Causes, clinical manifestations, and patient management are the same as for bradycardia.

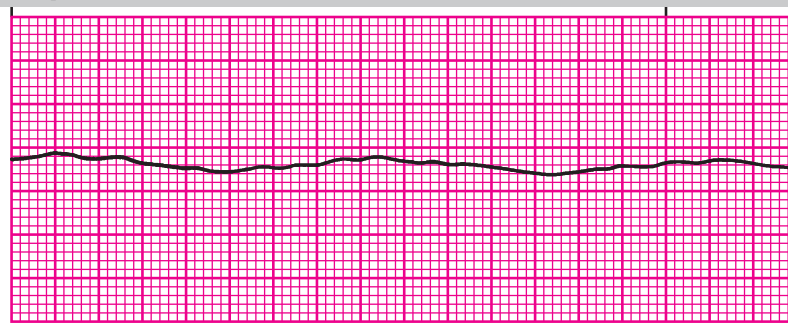
Too ugly: AV dissociation, VF, asystole

AV dissociation, also known as complete heart block or third-degree AV block, is a potentially life-threatening rhythm. Causes of this dysrhythmia are the same as for bradycardia. You'll see varied PR intervals in this dysrhythmia, and no relationship between the P waves and QRS complexes. In third-degree AV block, the SA node is usually working fine, so all of the P waves look the same and occur at regular intervals. But the block means these impulses aren't conducted to the ventricles. The ventricles generate their own impulses,

Coarse fibrillatory waves in VF



Asystole



resulting in wide and bizarre QRS complexes that occur at regular intervals, but have no consistent relationship to the P waves.

A patient with third-degree AV block will have loss of atrial kick and a decrease in ventricular rate. Depending on the ventricular rate, the patient can be significantly symptomatic.

Treatment, which is the same as for bradycardia, depends on the patient's clinical condition.

Because of their threat to life, the two ugliest rhythms are VF and asystole. VF is the result of many ventricular ectopic foci firing at once, resulting in an irregular, chaotic twitching of the ventricles without effective ventricular contractions. The patient will be apneic and pulseless. On ECG, you'll see a

totally irregular, chaotic rhythm of fine or coarse fibrillatory waves—you won't be able to discern P waves, QRS complexes, or T waves.

Call a code, start CPR, defibrillate the patient as soon as possible, and follow ACLS guidelines to improve his chances of survival.

Asystole is a flat or nearly flat line, indicating no cardiac electrical activity and therefore, no mechanical activity. Restoring a cardiac rhythm is very difficult once a patient is in asystole. Patient management includes high-quality CPR and other interventions following ACLS guidelines.

Toward a beautiful ending

If your patient has an abnormal cardiac rhythm, recognizing it as too fast, too slow, or too ugly can help you quickly anticipate the appropri-

ate interventions and intervene to give your patient the best chance at recovery. **NM**

RESOURCES

American Heart Association. 2005 American Heart Association guidelines for cardiopulmonary resuscitation and emergency cardiovascular care. *Circulation*. 2005;112(24, suppl 1):IV1-IV203. Thaler MS. *The Only EKG Book You'll Ever Need*. 5th ed. Philadelphia, PA: Lippincott Williams & Wilkins; 2007. Wagner GS. *Marriott's Practical Electrocardiography*. 11th ed. Philadelphia, PA: Lippincott Williams & Wilkins; 2007.

AnneMarie Palatnik is director of clinical learning in the Center for Learning at Virtua Health in Mount Laurel, N.J., and editor-in-chief of *Nursing2011 Critical Care*.

The author has disclosed that she has no financial relationships related to this article.

DOI-10.1097/01.NUMA.0000393322.62631.da

Erratum

Creating Cultures of Safety: Risk Management Challenges and Strategies

In the article that appeared on page 26 of the December issue, the reference numbers were listed incorrectly. The corrected version appears online.

Reference:

Raso R, Gulinello C. Creating cultures of safety: risk management challenges and strategies. *Nurs Manag*. 2010;41(12):26-33.

For more than 48 additional continuing education articles related to cardiovascular topics, go to NursingCenter.com/CE.

CE CONNECTION

Earn CE credit online:

Go to <http://www.nursingcenter.com/CE/NM> and receive a certificate within minutes.

INSTRUCTIONS

Too fast, too slow, too ugly: Dangerous dysrhythmias

TEST INSTRUCTIONS

- To take the test online, go to our secure website at <http://www.nursingcenter.com/ce/nm>.
- On the print form, record your answers in the test answer section of the CE enrollment form on page 35. Each question has only one correct answer. You may make copies of these forms.
- Complete the registration information and course evaluation. Mail the completed form and registration fee of \$24.95 to: **Lippincott Williams & Wilkins, CE Group**, 2710 Yorktowne Blvd., Brick, NJ 08723. We will mail your certificate in 4 to 6 weeks. For faster service, include a fax number and we will fax your certificate within 2 business days of receiving your enrollment form.
- You will receive your CE certificate of earned contact hours and an answer key to review your results. There is no minimum passing grade.
- Registration deadline is February 28, 2013.

DISCOUNTS and CUSTOMER SERVICE

- Send two or more tests in any nursing journal published by LWW together and deduct \$0.95 from the price of each test.

- We also offer CE accounts for hospitals and other health care facilities on nursingcenter.com. Call **1-800-787-8985** for details.

PROVIDER ACCREDITATION

Lippincott Williams & Wilkins, publisher of *Nursing Management*, will award 2.5 contact hours for this continuing nursing education activity.

LWW is accredited as a provider of continuing nursing education by the American Nurses Credentialing Center's Commission on Accreditation.

This activity is also provider approved by the California Board of Registered Nursing, Provider Number CEP 11749 for 2.5 contact hours, the District of Columbia, and Florida #FBN2454. Your certificate is valid in all states.

The ANCC's accreditation status of Lippincott Williams & Wilkins Department of Continuing Education refers to its continuing nursing education activities only and does not imply Commission on Accreditation approval or endorsement of any commercial product.