

Nonthrombotic Complications Related to Central Vascular Access Devices

ABSTRACT

Central vascular access devices (CVADs) provide reliable access for a variety of infusion therapies both in hospital and nonhospital settings. CVAD complications that are not identified and resolved can lead to a delay in therapy or the loss of vascular access. Rapid and accurate identification of complications is essential for obtaining expected treatment outcomes. This article will describe various nonthrombotic CVAD complications as well as identification and appropriate interventions used to manage these events.

Key words: catheter occlusion, nonthrombotic, precipitate occlusion

Complications related to vascular access devices often include restriction of flow, loss of patency, loss of blood return, and complete catheter occlusion. The *Infusion Nursing Standards of Practice* defines occlusion as “the inability to infuse or inject through a central venous catheter; inability to aspirate blood from a catheter or both.”^{1(pS106)} To be fully functional, a central venous catheter must flush without resistance and have a flowing blood return.

“It is estimated up to 25% of CVADs [central vascular access devices] develop occlusion problems.”^{2(p5)} These occurrences are frequent complications in health care settings and can significantly affect patient care. It is also well known that catheter occlusion can result from thrombotic and nonthrombotic causes. Early identification of catheter-related complications can minimize interruptions in the delivery of infusates and allow for greater ease of restoring full functional use.

Prevention, proper identification, and appropriate treatment strategies must be integrated into practice to achieve optimal patient outcomes related to catheter occlusion. Prevention requires attention to the causes of occlusion. It is important to apply appropriate assessment criteria to determine the etiology of the occlusion before intervention.³ The nature of the occlusion must be identified so appropriate treatment can be initiated.⁴ Nonthrombotic causes account for 42% of catheter occlusions. The remaining 58% of occlusions are thrombotic, caused by a blood clot within the catheter.² Accurate identification of cause and application of appropriate treatment for the specific type of occlusion will result in the best outcome.

Author Affiliations: Via Christi Health, Wichita, Kansas (Mr D. Ast); Baylor University Medical Center, Dallas, Texas (Dr T. Ast).

Daniel Ast, MS, RN, CRNI®, has more than 30 years of experience in an acute health care environment. He has been in director, management, and staff positions, and has spent much of his career involved in intravenous therapy services at Via Christi Health. Mr. Ast is an educator and a coauthor of previous infusion-related publications.

Travis Ast, PharmD, is a resident pharmacist at Baylor University Medical Center in Dallas, Texas.

Corresponding Author: Daniel Ast, MS, RN, CRNI® (e-mail: daniel.ast@via-christi.org).

The authors of this article have no conflicts of interest to disclose.

DOI: 10.1097/NAN.0000000000000063

ETIOLOGY AND ASSESSMENT FOR NONTHROMBOTIC OCCLUSIONS

When a catheter becomes resistant to flush or infuse, or has an absence of blood return, it should be assessed immediately for cause. To continue its use, the catheter should be restored to full function. Failure to address and resolve these complications can result in unnecessary and serious risk to the patient, including venous catheter loss and catheter infection from bacterial or fungal colonization. The goal is to restore catheter function safely and efficiently to achieve positive patient outcomes.

Incorrect diagnosis for the etiology of nonthrombotic occlusion can result from incomplete assessment because many of the signs and symptoms are related to different causes. A thorough review of the history, relevant signs, and symptoms—and an accurate determination of cause—will help identify the appropriate treatment plan. Presenting signs and symptoms include frequent infusion pump alarms, the inability to infuse or withdraw, and increased resistance when flushing.⁵ Although these signs and symptoms indicate occlusion, they do not define the cause. Accurate determination of cause requires further review of all characteristics of the occlusion.

Nonthrombotic catheter occlusion generally occurs as a result of 1 or more causes. Mechanical obstructions external to the insertion site can result from kinked administration sets or catheters. Internal causes of a mechanical nature, such as catheter malposition and migration, also account for causes of nonthrombotic occlusion. In addition, drug or mineral precipitates and lipid residue from parenteral nutrition (PN) admixtures can contribute to these occlusions.⁴

MECHANICAL CAUSES OF OCCLUSION

“Whenever a catheter occlusion is identified, the clinician’s first step should always be to rule out possible mechanical obstruction. Many causes for mechanical occlusions are easy to detect and resolve.”^{4(p12)}

These occlusions can result from causes external or internal to the insertion site. When external causes are not identified, radiographic review may be indicated to visualize the catheter course and end-tip location for possible internal causes. Catheters that are tunneled through tissue can kink before entering the vessel or after entering the vasculature. Catheter end tips can also abut the vessel wall, preventing flow and blood return.

Finding the cause of a mechanical occlusion is essential to restoring catheter function. Accurate and timely assessment for cause will result in the avoidance of unnecessary intervention, expense, and patient exposure to inappropriate use of dissolving agents.

External Mechanical Occlusions

Assessment to identify the cause of an external occlusion involves examining various components of the vascular access device external to the insertion site. Abrupt loss of flow or blood return can indicate an external mechanical occlusion. Check for kinks or clamping of the external catheter or tubing. Rule out filters which may become clogged and result in loss of flow. Check the securement device or suture for constriction of the catheter.⁴

It may be necessary to remove the sterile dressing to examine the catheter and securement device for potential causes of occlusion (Figure 1). These are common causes of external mechanical occlusions that can be easily overlooked without a thorough inspection of all external components of the vascular access device. Once identified, many mechanical occlusions can be resolved by correcting the cause.

Internal Mechanical Occlusions

There are many factors to consider when assessing for mechanical occlusions internal to the insertion site. These occlusions may result from kinks in the tissue or vasculature, end-tip location, migration, malposition, pinch-off syndrome, and implanted port failure. Assessment for each of these potential causes of internal mechanical occlusion requires the practitioner to explore all related factors.

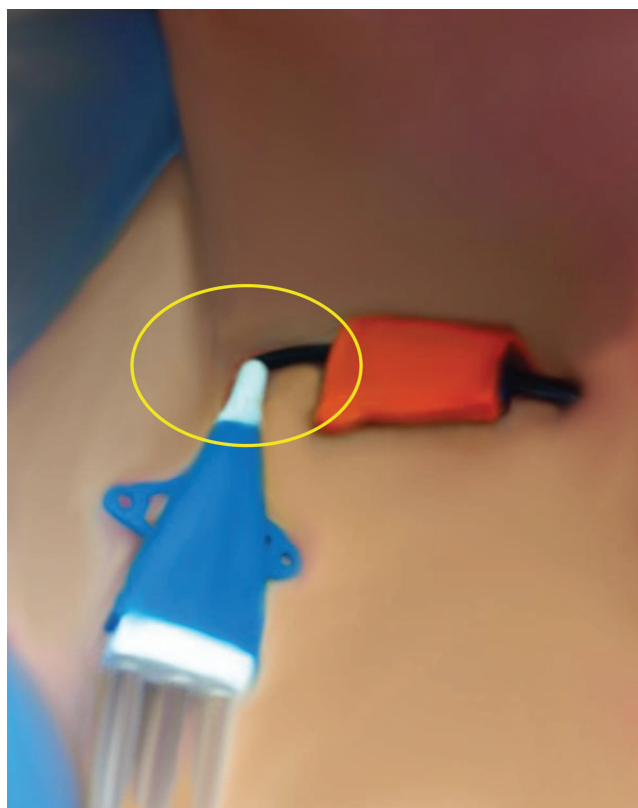

Figure 1 Catheter with securement device is kinked external to the insertion site.

Kinks in tissue or vasculature internal to the insertion site can cause mechanical occlusions

Initially, the securement device should be examined for constriction of the catheter at the insertion sight. Because of the anatomical nature associated with external or internal jugular catheters, they can kink internally and occlude with the patient's movement of his or her head and neck. Partial or complete occlusions can result. Assessing catheters with radiography can identify a kink in the tissue near the insertion site and in the vasculature (Figure 2).

Migration of the catheter and end tip can result in an internal mechanical occlusion

Catheter end-tip location can be the cause of resistance when flushing or the loss of blood return. Migration can displace the catheter end tip near or abutting the vessel wall. If the end tip abuts the vasculature, infusates may flow, but blood return may be absent. Peripherally inserted central catheters (PICCs) inserted from a left arm approach, when length does not allow distal superior vena cava (SVC) positioning of the tip, can result in the end tip abutting the lateral wall of the SVC. By using radiographic study, the practitioner is able to identify this migration and resulting malposition (Figure 3).

Catheters can also migrate upward. "The most common place for a catheter in the SVC to migrate is to the jugular system."^{4(p13)} With malpositions to the jugular system, patients frequently will hear a flushing sound when normal saline is instilled. Although malpositions of this type can result in thrombotic occlusions, the

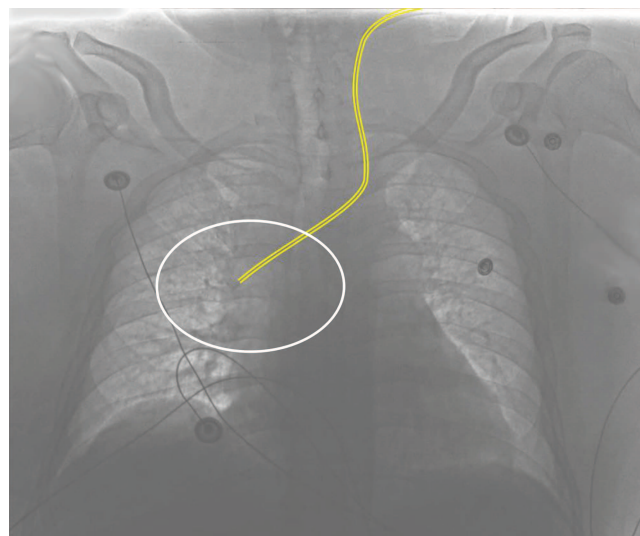


Figure 3 Left-sided PICC (highlighted in yellow) with end tip abutting lateral wall of the SVC.

need for catheter clearance medications can be ruled out when a mechanical cause is identified. When internal mechanical occlusion is suspected and followed by radiographic study, migration with resulting end-tip position can be identified as the cause.

Malpositioned catheters can also be the source of mechanical occlusion

"The primary sign of malposition is an inability to infuse or withdraw from the catheter."^{4(p13)} It is important to assess additionally for external catheter length, arm or shoulder discomfort, and arrhythmias.⁴ Catheter malpositions can occur at the time of insertion and during dwell time. They can occur with or without migration of the catheter at the insertion site. Catheters can malposition to the contralateral innominate vessel or up the jugular vessels and can curl and kink as a result. Cardiac monitoring may detect arrhythmias triggered by low catheter end-tip placement at the junction of the SVC and the right atrium. A radiographic study can identify and confirm the malposition.

Although uncommon, pinch-off syndrome can be an internal cause of catheter occlusion

Anatomically, the costoclavicular space is bound posteriorly by the first rib and anterior scalene muscle and anteriorly by the clavicle and subclavius muscle.³ In this syndrome, the central venous catheter passes between the clavicle and first rib alongside the subclavian vein. The subclavian vein, as well as the catheter in the costoclavicular space, is susceptible to compression. When the patient is in an upright position, the angle narrows, and the catheter, unprotected outside of the subclavian vein, is compressed. The catheter compression at the

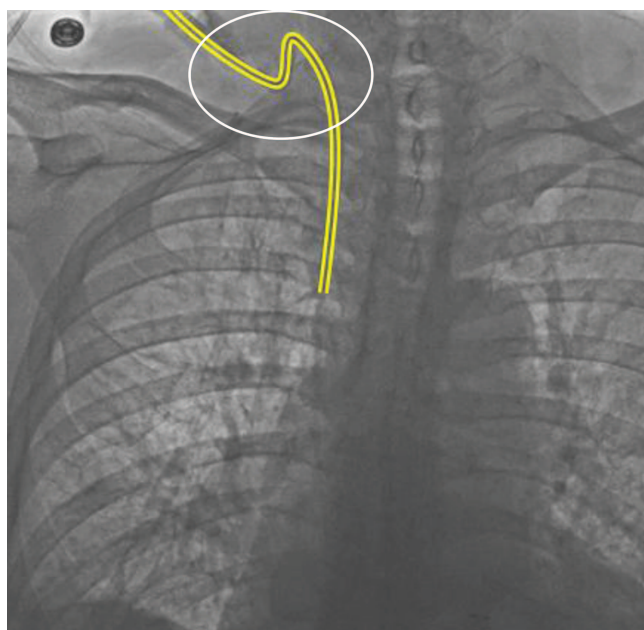


Figure 2 Radiographic identification of internal catheter kink (highlighted in yellow).

costoclavicular space, as it appears on chest x-rays, has been termed the *pinch-off sign* (Figure 4).⁶

Part of the initial assessment for pinch-off syndrome should include location of the insertion site. Subclavian catheter insertion more medial to the midclavicular line can be an indication of this syndrome.³ “The key is the intermittent positional nature of the occlusion. Rolling the shoulder or raising the arm on the ipsilateral side will open the costoclavicular space and relieve the impingement of the catheter allowing flow. This is an important assessment criterion and is a hallmark of pinch-off syndrome.”^{7(p235)} Intermittent catheter malfunction, in addition to radiographic evidence of compression, is indicative of pinch-off syndrome.^{3,8} Radiographic examination is indicated to confirm pinch-off syndrome when assessment reveals these findings.⁴

Catheter fracture is a complication of pinch-off syndrome that requires attentive assessment skills

“Although uncommon, ‘pinch-off syndrome’ and catheter fracture are reported complications of central venous catheters.”^{3(p1227)} Although this complication is associated with mechanical occlusion, it is not a cause. Compression of the catheter, as seen with pinch-off syndrome, can result in fracture.³ “Central venous catheter fracture with subsequent migration of the distal catheter fragment into the right side of the heart or the pulmonary artery is a serious consequence of catheter trauma.”^{3(p1229)} In addition, extravasation can result if catheter fracture is not identified and vesicant or irritant infusions infiltrate the tissue at the fracture site. Pain during infusion in the chest area surrounding the fracture may be the presenting symptom. Loss of blood return may also be observed. Thorough assessment skills and diagnostic evaluation with contrast will confirm catheter fracture (Figure 5).

Complications associated with implanted ports can also result in mechanical occlusions

Improper location of the external access device in the port septum can be the cause of occlusion.⁹ The port should be assessed at the access site for swelling or edema and tenderness when palpating. In addition,

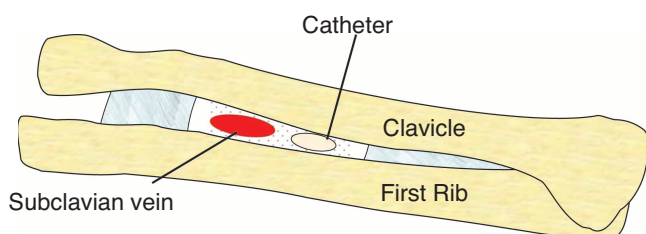


Figure 4 Illustration of pinch-off syndrome with compression of subclavian and catheter.

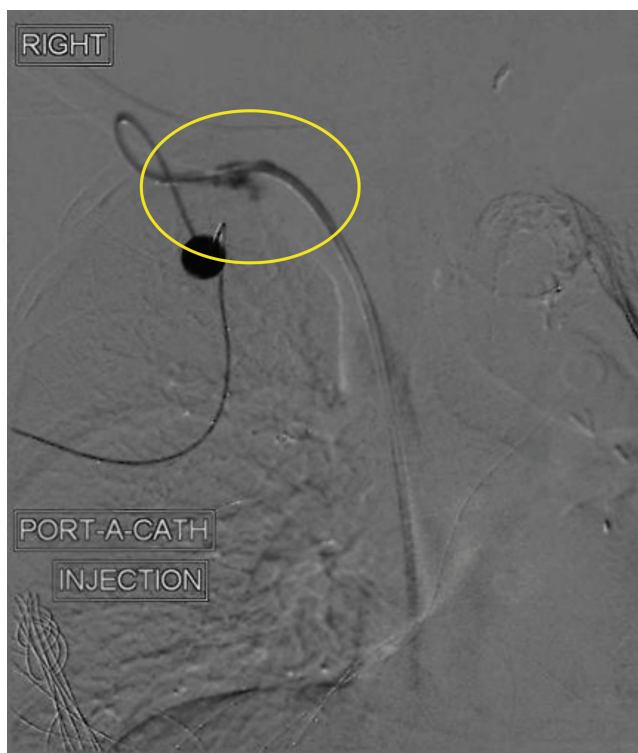

Figure 5 Contrast injection of port identifying catheter fracture.

patency and blood return should be assessed. These findings may indicate that the access device is not in the septum. If misplacement of the access device is suspected, the device should be removed and the port should be reaccessed. If function is not restored following reaccess, further assessment for cause is indicated. Radiographic study of the access may verify accurate placement of the device in the septum (Figure 6).

Fluoroscopy study of an implanted port may be indicated when the placement of the device has been ruled out as the cause of the occlusion. In a patent port, contrast can be visualized at the catheter's distal tip, and the integrity of the port can be observed. During a fluoroscopy study, the inability to inject and visualize contrast at the catheter end tip may indicate an obstruction. If detected, a leak of contrast media will indicate that the port is no longer intact. In this case, surgical explantation should be pursued.

DRUG OR MINERAL PRECIPITATE CAUSES OF OCCLUSIONS

Precipitate occlusions can be caused by drug or mineral interactions. Awareness of such infusates and those especially at high risk for precipitation may help identify the causes of these occlusions.

Drug Precipitate Occlusions

Hadaway^{10(p58)} states: “when incompatible drugs come in contact with each other, a physiochemical reaction

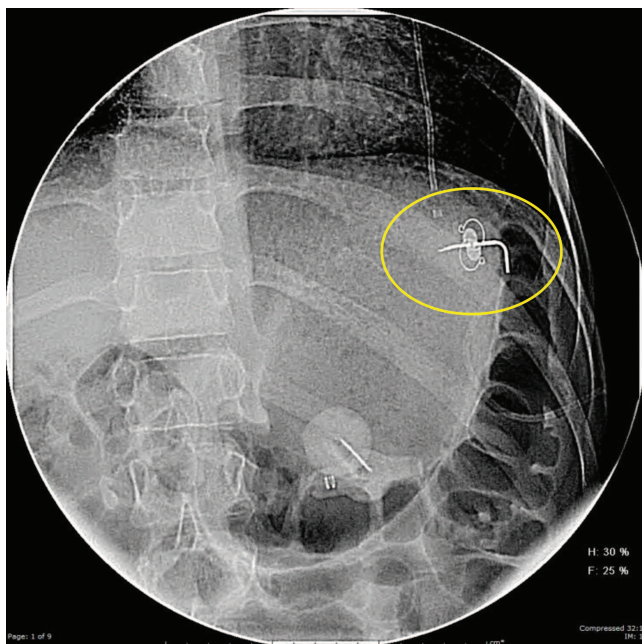


Figure 6 Fluoroscopic view of port access device in correct position within the septum.

changes the solutions' physical properties and precipitation forms. The degree of incompatibility depends on such factors as how long the drugs are in contact, the mixing sequence, light exposure, and temperature." Precipitate occlusions typically occur suddenly after the administration of 2 incompatible solutions.¹¹ Assess for abruptness of the occlusion.

It's important to be aware of infusates, such as phenytoin or heparin, which are at high risk for precipitation.¹² There are numerous interactions with heparin, such as morphine, dobutamine, and erythromycin. When proper flushing with saline is not accomplished, precipitation from heparin incompatibility can result.⁴ If no information is available, the infusates should be considered incompatible. If precipitate occlusions are suspected, a pharmacist should be consulted to help identify potential drug incompatibilities.

Mineral Precipitate Occlusions

Calcium-phosphate precipitation should be suspected when patients are receiving increased levels of the electrolytes in PN solutions. The ratio of calcium to phosphate in PN is directly related to the development of calcium-phosphate crystallization.¹³ Premature infants often require increased concentrations of calcium, phosphorus, and magnesium; therefore, these solutions are more susceptible to a mineral precipitate occlusion. The minerals have limited solubility at higher concentrations.¹⁴ Awareness of the potential for mineral precipitation will assist practitioners with assessment and determination.

Lipid Residue Occlusions

A recent study identified lipid emulsions as an important risk factor for catheter occlusion.¹⁵ Examination of occluded catheters after administration of total nutrient admixtures has shown a waxy residue.⁴ Intraluminal deposits of this waxy lipid material can occlude the catheter completely.

"Occlusion due to lipid deposition occurs only when three-in-one mix is used."^{13(p417)} When infusing PN solutions containing lipids, lipid micelles can become trapped in the lumen where fibrin buildup has occurred. This creates a unique occlusion of protein and lipid, requiring a specific agent for clearing.¹⁵ When a 3-in-1 solution is being administered, lipid residue should be suspected if occlusions occur.

PREVENTION AND TREATMENT OF NONTHROMBOTIC OCCLUSIONS

Effective management of nonthrombotic occlusions requires both prevention and treatment strategies. The catheter should be assessed before, during, and after each infusion to monitor for integrity and alignment. Once an occlusion is identified and the etiology has been determined, the appropriate treatment must be initiated. Successful treatment of nonthrombotic occlusions can prevent catheter loss, preserve vessels, avoid invasive procedures, and decrease associated costs for replacement.⁹

Prevention and Treatment of Mechanical Occlusions

Prevention of mechanical occlusions requires attention to both external and internal factors. Being attentive to potential causes of these occlusions and implementing preventive strategies can minimize the need for intervention. Attention should be focused on the insertion site, tubing, filters, connections, and external segments of the catheter.

Insertion sites near joints or areas of flexion, such as vessels of the neck region, are more prone to mechanical occlusion. Consideration should be given to the location of the insertion to avoid and minimize this complication. When using devices such as an infusion pump, it is important to manage kinks that may occur in or around the device. By raising or lowering the height of the intravenous pole, administration sets can be suspended in a way to avoid kinking. Tubing connections should be securely placed with luer-lock-design connectors to ensure that the device is properly open for infusion. Filters should be changed at recommended intervals and be inspected for potential occlusion whenever flow rates or infusion pump alarms are identified. Before performing dressing changes, the external catheter segment

should be examined to identify potential causes of occlusion. Such causes may be identified in patients with an internal or external jugular placement in which positional changes are likely to result in kinking. Repositioning of the catheter and reapplying the dressing may help avoid kinking that may be caused by anatomical factors associated with positional changes. Securement devices used at the insertion site should also be examined and placed appropriately to avoid this complication. Prevention and treatment of internal occlusions can be managed with attention to insertion of the device and end-tip placement.

To prevent the incidence of pinch-off syndrome, the ideal insertion location should be at or lateral to the midclavicular line.⁷ Catheter compression is more likely to occur if the catheter is surgically placed medial to the midclavicular line. This approach positions the catheter alongside, rather than inside, the lumen of the subclavian vein. The catheter, when passed through the costoclavicular space inside the lumen of the subclavian vein, is afforded greater protection from compression.³ Other prevention strategies for pinch-off syndrome include insertion through the internal jugular vein or the basilic and cephalic vessels of the upper arm.¹¹ With these insertion sites, the catheter avoids the area of compression in the costoclavicular region and eliminates the chance of pinch-off syndrome. Opportunity exists to educate physicians about preventive measures, such as lateral catheter insertion technique, radiographic monitoring, and prompt catheter removal when pinch-off is identified.³ In pinch-off syndrome, treatment requires immediate removal of the catheter.⁶

The end tip of a CVAD should dwell in the SVC close to the junction with the right atrium.¹¹ Catheters with end tips terminating in the proximal SVC can malposition to the jugular system and may result in partial occlusion or loss of blood return.⁴ By proper positioning of the end tip at the time of insertion, mechanical occlusions of this nature can be prevented.

After radiographic study identifies an internal cause, appropriate intervention should be initiated. If kinks are identified within the tissue at the insertion site, and catheter length allows, slight retraction of the catheter may relieve the kink and restore function. When radiographic assessment identifies end-tip abutment of the vessel wall as a potential cause, slight retraction of the catheter may also resolve the occlusion. If catheter retraction is performed to resolve these issues, it is necessary to reassess end-tip location for placement within the SVC. If end-tip location in the SVC cannot be maintained, the catheter should be removed.

Prevention and Treatment of Precipitate Occlusions

Prevention and treatment of precipitate occlusions are managed with a knowledgeable understanding of infusate

compatibility, preparation and administration methods, acidic or alkaline properties of infusates, and intraluminal lipid residue buildup. Certain medications are notorious for intraluminal precipitation. Being aware of these drugs will be helpful when identifying potential causes of occlusion.⁴ For example, drugs prone to intraluminal precipitation include diazepam, calcium gluconate, and phenytoin.⁴ Other common precipitates result from heparin incompatibilities. Examples of drugs incompatible with heparin are amikacin, codeine, cytarabine, daunorubicin, dobutamine, erythromycin, gentamicin, hyaluronidase, kanamycin, levorphanol, meperidine, methadone, morphine, polymyxin B, promethazine, and streptomycin.^{4,16}

To prevent precipitate occlusion caused by 2 or more drugs infused together, incompatibilities should be checked before infusion. If the compatibility of infusates cannot be determined before administration, a pharmacist should be consulted to ensure the solutions are compatible when infused together. The use of separate lumens can significantly reduce the chance of precipitation. If multiple lines cannot be used, adequate flushing with at least 10 mL of sodium chloride (NaCl) should be performed between infusates.¹¹ Adequate flushing between medications is imperative to prevent precipitate occlusions.⁴ Infusion Nursing Standard of Practice 45.2 states, "Vascular access devices shall be flushed after each infusion to clear the infused medication from the catheter lumen, preventing contact between incompatible medications."^{1(p170)} The saline-administer-saline-heparin (SASH) technique is recommended to prevent precipitation of incompatibles.¹³ Push-pause technique can also be used to create turbulence inside the catheter lumen during flushing and to reduce the risk of occlusion.¹³

Compounding methods to prevent precipitate formation are accomplished by increasing solubility during pharmaceutical preparation. Among these strategies are changing the pH, mixing additives in correct order, ensuring appropriate solution temperature during preparation, and maintaining concentrations within safe parameters.^{4,17} When in question, information about the acidic and alkaline properties of the infusates and the likeliness of precipitate formation can be obtained by consulting with the pharmacist.

Because of the ease of managing PN and lipid infusions in the home setting, 3-in-1 mixes are common. Avoiding these solutions in combination, when possible, will prevent a lipid residue occlusion.¹⁴ Practitioners should be mindful that occlusions may occur slowly over time when using 3-in-1 solutions.¹⁴ Complete occlusions can be prevented if detected early.¹⁴ Before administration, PN 3-in-1 solutions should be inspected closely for visible signs of precipitation and should not be administered if observed.¹³ Filtering these infusions during administration is required and may become a source of occlusion. Regular flushing with ethanol

alcohol (EtOH) has been shown to reduce the incidence of PN 3-in-1 precipitation.¹⁴ In addition, using PN solutions in the first 28 hours after preparation can significantly decrease the risk of lipid buildup in the catheter.¹³ Infusion Nursing Standard of Practice 56 discusses thrombotic and precipitate occlusions in CVADs.¹ The practice criteria identify medications and solutions used to dissolve deposits or precipitates, such as 0.1 N hydrochloric acid (HCl), sodium bicarbonate, sodium hydroxide (NaOH), and ethyl alcohol for specific precipitate occlusions.¹ Depending on the alkaline or acidic properties of the precipitate, instillation of sodium bicarbonate or HCl, respectively, can clear the occlusion.⁹ In addition, NaOH can be used to dissolve alkaline precipitates.⁵ These agents are safe and effective in the proper concentrations and volumes when used to dissolve precipitates.^{4,15,17,18} In addition, 0.1 N HCl can be administered without resulting in damage to the catheter material.¹⁹


There is a simple way to remember the agents indicated for alkaline or acid precipitates: to dissolve an alkaline or base precipitate requires an agent that is

chemically a base⁴; to dissolve an acidic precipitate requires an agent that is chemically an acid.⁴

Identifying the cause of nonthrombotic occlusion and determining the appropriate treatment is essential (Table 1).

Treatment of alkaline precipitate occlusions can be managed with the appropriate dissolving agent

Because the dissolution of drug precipitates are pH dependent, consulting the pharmacist can be helpful in determining the most appropriate solvent.¹¹ “The goal in treating precipitates is to increase the solubility of the precipitate by changing the pH within the catheter lumen.”^{5(p603)} When alkaline precipitation is the suspected cause of the occlusion, use sodium bicarbonate (8.4%).¹¹ The use of NaOH (0.1 N) is also effective in dissolving alkaline precipitations.⁵ The dose to be instilled is 1 mL or an amount equal to the catheter-lumen volume. Dwell time for this agent inside the catheter should be 60 minutes. After 60 minutes, the catheter should be aspirated and its contents discarded.

<div>  TABLE 1 Diagnosis and Treatment </div>			
Nonthrombotic Occlusions: Diagnosis and Treatment			
Etiology	Identification	Treatment	Guidelines
Mechanical	Inability to flush or aspirate line Examination of external line, securement device, clamps, and sutures as possible causes Radiographic imaging may be necessary for identification of internal mechanical occlusions	Based on examination, external kinks can be easily resolved by repositioning the catheter and reapplying sterile dressing Internal mechanical occlusions may require adjustment of the catheter Removal of the catheter may be necessary if complication remains unresolved	
Drug or mineral precipitate	Occlusion occurs suddenly during administration Recent infusion of incompatible drugs (eg, heparin, morphine, erythromycin, and dobutamine) High-risk infusates for precipitation (eg, phenytoin and heparin) High concentrations of calcium and phosphorous in parenteral nutrition solutions	Alkaline/high pH (9-12): Sodium bicarbonate (8.4%) or sodium hydroxide (0.1 N) Acidic/low pH (1-5): Hydrochloric acid (0.1 N) Calcium phosphate: Hydrochloric acid (0.1 N) or L-cysteine hydrochloride ^a	Instill 1 mL (or amount equal to the intraluminal volume) [<i>pediatric dose: 0.2-1 mL</i>] ²⁰ Allow dwell time of 60 minutes Attempt to aspirate and discard Flush with 10-20 mL of sodium chloride (0.9%) May repeat if occlusion remains unresolved Attempts beyond 24 hours may be ineffective ¹⁷
Lipid residue	Occlusion appears slowly over time with increased resistance ¹⁴ Recent infusion of 3-in-1 solutions Rule out filter occlusion prior to treating with agents	Ethanol (70%) for mainly lipid or Sodium hydroxide (0.1 N) for both lipid and protein <i>May combine both agents for treatment if a single agent fails to clear the line</i>	Instill 10 mL of the selected agent over 60 minutes. [<i>pediatric dose: 3-5 mL ethanol or 1 mL sodium hydroxide</i>] Lock catheter and allow for a dwell time of 2 hours Attempt to aspirate and discard Flush with 10-20 mL of sodium chloride (0.9%) May repeat if occlusion remains unresolved ²⁰

^aNot an FDA-approved indication.

It should then be flushed with an adequate amount of NaCl (0.9%) solution to clear the catheter.²¹

For pediatric patients, 0.2 to 1.0 mL sodium bicarbonate or 1 mL NaOH (0.1 N) can be instilled.²⁰ If necessary, the process can be repeated. The concentration of the agent is the same for both adult and pediatric treatment. The volume is adjusted accordingly for the approximate prime volume of the catheter being treated. For example, an implanted port will require a larger volume than a PICC. To avoid systemic administration of dissolving agents, consult manufacturer guidelines to ascertain prime volumes specific to the catheter being treated before instilling.

Treatment of acidic precipitate occlusions is accomplished with HCl (0.1 N) as the agent of choice

This agent must be extemporaneously compounded for the strength indicated for this treatment; directions for preparation have been published in various sources.^{4,22-24} Instill 1 mL or an amount equal to the filling volume.⁴ Clamp and allow wait time recommended by the manufacturer. One source allowed dwell time greater than 1 hour.¹⁷ The agent should be aspirated and discarded after dwell time.⁴ Instillation may be repeated once or twice. Once patency is restored, flush the catheter with 10 to 20 mL of NaCl (0.9%) and resume use.⁴ If it is not cleared after 24 hours, further efforts with HCl will not be effective.¹⁷

For pediatric patients, inject 0.2 to 1 mL of HCl (0.1 N). Repeat if necessary.²⁰ It is important to adjust the volume instilled for pediatric application for the device being treated. Practitioners should take care to avoid accidental splashing on the skin and eyes during instillation of these agents. In addition, clinicians should be aware that direct infusion of HCl into the venous system can be associated with fever, phlebitis, and sepsis. The solution should always be aspirated and discarded when the procedure is completed.⁴

Treatment of calcium-phosphate precipitates is accomplished with HCl as an agent of choice

Calcium-phosphate precipitation is a mineral precipitate that results in a low pH. This precipitate can be treated with HCl (0.1 N).^{14,17} Instill 1 mL or an equal amount to the filling volume.⁴ Clamp and allow wait time recommended by the manufacturer. The agent should be aspirated and discarded after dwell time.⁴ Instillation may be repeated once or twice. Once patency is restored, flush the catheter with 10 to 20 mL of NaCl (0.9%) and resume use.

In pediatric patients, one source recommends the instillation of 0.5 mL HCl (0.1 N) through a 1-mL syringe injected with a gentle push-pull method over 1

to 2 minutes.²⁰ Refer to instillation methods below for negative-pressure techniques to avoid catheter rupture. If the occlusion is not immediately resolved, the catheter is locked with the solution in place and the process can be repeated until cleared or when deemed unsuccessful.²⁰ For calcium-phosphate precipitates, the concentration of agent is the same as for adults. The volume instilled is adjusted for the specific device to address appropriate dosing for pediatric application.

Cysteine HCl, which is available commercially, has been identified in the literature to decrease the pH of TPN solutions and increase calcium-phosphate solubility for neonates.^{4,25,26} Cysteine is an amino acid approved by the US Food and Drug Administration as an additive for infant preparations. Use of cysteine for dissolution of precipitates is an “off-label” indication. Because of associated risks with HCl and the costs and time involved in compounding, it seems cysteine could be an appropriate option for this indication.

Treatment of lipid residue occlusions is accomplished with the use of EtOH (70%)

This agent has been proved the most successful when treating an intraluminal occlusion caused by mainly lipid residue.⁴ Although not always possible, it may be helpful to determine if the obstruction is mainly lipid or fibrin in order to identify the best agent for clearing the obstruction.²⁷ If the occlusion is mainly fibrin, EtOH (70%) is ineffective.²⁷

In the literature, 2 authors report that when TPN solutions containing lipids are infusing and fibrin buildup is suspected, NaOH is the only effective agent to act on both protein and lipid precipitates. However, Sando et al²⁷ argue that NaOH cannot dissolve occlusions caused mainly by lipid buildup, but can dissolve occlusions that mainly contain fibrin. Furthermore, he concludes, a combined treatment using EtOH (70%) and NaOH (0.1 N) is safe and may result in improved success rates.²⁷ A treatment combining both agents may be used if 1 of the agents is unsuccessful in clearing the occlusion.²⁷

To clear lipid precipitates, instill 10 mL of NaOH (0.1 N) or EtOH (70%) over 60 minutes, then lock the catheter lumen for 2 hours.¹¹ It is important to follow manufacturer guidelines with regard to the use of solutions such as EtOH (70%) in certain catheter materials. Studies have shown that the integrity of polyetherurethane catheters remains intact following administration of EtOH (70%).²⁸ It is recommended, however, that the manufacturer's guidelines specific to the catheter type used be reviewed whenever alcohol solutions are instilled.^{4,10,21}

In pediatric patients, 3 mL of EtOH (70%) can be injected and left to dwell for 1 to 2 hours. This procedure can be repeated once if the occlusion is not completely cleared.²⁰ If unsuccessful, 1 mL of NaOH (0.1 N) is an appropriate second option.²⁰

Instillation Methods of Treatment Agents

“Consideration should be given to the potential pressure exerted on an occluded CVAD when medications and/or solutions used for catheter clearance are instilled. The syringe size used for catheter clearance procedures should be no smaller than 10 mL and should be in accordance with the catheter manufacturer’s directions for use. Instillation methods that use a negative-pressure approach should be considered.”^{1(pS77),29,30} Both stopcock and syringe methods can be used as a negative-pressure approach, and both prevent catheter rupture during the instillation process.³¹ Negative-pressure methods should always be used for complete occlusions. If a complete occlusion has not occurred and the device is patent, direct instillation of agents can be performed.

Use of a 3-way stopcock is a negative-pressure method for instilling catheter clearance agents into occluded catheters. With the stopcock initially turned off to the agent, the practitioner aspirates 8 to 9 mL of air with a 10-mL syringe attached to the stopcock. This creates negative air space in the catheter. With a second syringe containing the agent attached to the stopcock, the stopcock can be turned off to the air syringe, which allows the agent to fill the negative air space.³¹

Using a 2-syringe method, the practitioner can also accomplish safe instillation of catheter clearance agents without risk of catheter rupture. With this method, an empty sterile 10-mL syringe is attached to the catheter hub, and 8 to 9 mL of air is aspirated into the syringe to create a negative air space within the catheter.³¹ The catheter is then clamped, and the syringe is removed and replaced with a 10-mL syringe containing the clearance agent. When the catheter clamp is reopened, the agent is drawn into the negative air space previously created. Repeated attempts may be necessary to achieve instillation of the recommended volume of the agent.²⁰

Direct instillation requires a gentle push-and-pull method. A syringe size of 5 to 10 mL is often recommended to decrease the pressure of injection; however, a greater degree of control is afforded with the use of a 3-mL syringe in the hands of an experienced clinician. When performing the declotting procedure with a syringe method, be sure to keep the dissolving agent at the base of the syringe when releasing the plunger. This ensures delivery into the negative air space that is created.³²

CONCLUSIONS

Nonthrombotic catheter occlusions account for a significant number of complications associated with loss of patency or failure to obtain blood return. Because these occlusions require specific treatment measures, assessment and accurate determination of cause is critical. Prevention is key to eliminating occlusions and minimizing the use of clearing agents to treat these occlusions.

Whenever an occlusion is identified, the cause must be identified so that appropriate treatment can be initiated. Whereas mechanical occlusions can be treated without a chemical agent, precipitate and lipid residue occlusions require the use of specific agents. Most agents used for treating nonthrombotic occlusions require special preparation and compounding techniques, add cost, and complicate treatment.

A literature review on this topic has identified that further development is needed to benefit practitioners and patients. Although safe treatment with agents for nonthrombotic occlusions has been studied and documented for many years, their use in clinical practice is not widespread. Because the treatment agents discussed in this manuscript require complicated, time-consuming, and costly preparation methods, their access is difficult and inefficient. Further study and development in this area would assist practitioners in implementing these treatments and improving outcomes for patients who experience these complications.

REFERENCES

1. Infusion Nurses Society. Infusion nursing standards of practice. *J Infus Nurs.* 2011;34(suppl 1):S1-S110.
2. Cleaves S, Earhart A, Meaux N, for the Infusion Nurses Society. New standards for catheter occlusion management. In: *Nurs Pract Manage.* 2008;1(2):2-12.
3. Nace CS, Ingle RJ. Central venous catheter “pinch-off” and fracture: a review of two under-recognized complications. *Oncol Nurs Forum.* 1993;20(8):1227-1236.
4. Herbst SL, Kaplan LK, McKinnon BT. Nonthrombotic catheter occlusions and their treatment. *Infusion.* 1998;4(8):12-17.
5. Phillips L. *Manual of IV Therapeutics.* 5th ed. Philadelphia, PA: FA Davis Co; 2010.
6. Aitken DR, Minton JP. The “pinch-off sign”: a warning of impending problems with permanent subclavian catheters. *Am J Surg.* 1984;148(5):633-636.
7. Andris DA, Krzywda EA. Catheter pinch-off syndrome: recognition and management. *J Infus Nurs.* 1997;20(5):233-237.
8. Hinke DH, Zandt-Stastny DA, Goodman LR, Quebbeman EJ, Krzywda EA, Andris DA. Pinch-off syndrome: a complication of implantable subclavian venous access devices. *Radiology.* 1990;177(2):353-356.
9. Doellman D. Prevention, assessment, and treatment of central venous catheter occlusions in neonatal and young pediatric patients. *J Infus Nurs.* 2011;34(4):251-258.
10. Hadaway LC. Reopen the pipeline for IV therapy. *Nursing.* 2005;35(8):54-61.
11. Hadaway LC. Managing vascular access device occlusions, part 2. *Nursing.* 2000;30(8):13-14.
12. Baskin JL, Pui C-H, Reiss U, et al. Management of occlusion and thrombosis associated with long-term indwelling central venous catheters. *Lancet.* 2009;374(9684):159-169.
13. Gorski LA. Central venous access device occlusions: part 2: nonthrombotic causes and treatment. *Home Healthc Nurse.* 2003;21(3):168-171.
14. Werlin SL, Lausten T, Jessen S, et al. Treatment of central venous catheter occlusions with ethanol and hydrochloric acid. *J Parenter Enteral Nutr.* 1995;19(5):416-418.

15. Bader SG, Balke P, Jonkers-Schuitema CF, Tas TA, Sauerwein HP. Evaluation of 6 years use of sodium hydroxide solution to clear partially occluded central venous catheters. *Clin Nutr.* 2007;26(1):141-144.
16. Trissel L. *Handbook of Injectable Drugs*. 17th ed. Bethesda, MD: American Society of Health-System Pharmacists; 2012.
17. Shulman RJ, Reed T, Pitre D, Laine L. Use of hydrochloric acid to clear obstructed central venous catheters. *J Parenter Enteral Nutr.* 1988;12(5):509-510.
18. Ter Borg F, Timmer J, De Kam SS, Sauerwein HP. Use of sodium hydroxide solution to clear partially occluded vascular access ports. *J Parenter Enteral Nutr.* 1993;17(3):289-291.
19. Moreno JM, Valero MA, Gomis P, León-Sanz M. Central venous catheter occlusion in home parenteral nutrition patients. *Clin Nutr.* 1998;17(1):35-36.
20. Kerner JA Jr, Garcia-Careaga MG, Fisher AA, Poole RL. Treatment of catheter occlusion in pediatric patients. *J Parenter Enteral Nutr.* 2006;30(suppl 1):73-81.
21. Hadaway LC. Managing vascular access device occlusions, part 2. *Nursing.* 2009;39(3):13-14.
22. Thompson B, Veal D. Pharmacological treatment of pediatric catheter occlusions. *Hosp Pharm.* 1992;27:137-141.
23. Stennett DJ, Gerwick WH, Egging PK, et al. Precipitate analysis from an indwelling total parenteral nutrition catheter. *J Parenter Enteral Nutr.* 1988;12(1):88-92.
24. McKinnon BT, Avis KE. Membrane filtration of pharmaceutical solutions. *Am J Hosp Pharm.* 1993;50(9):1929-1936.
25. Canada T, Albrecht J. Parenteral calcium gluconate supplementation: efficacious or potentially disastrous? *J Am Coll Nutr.* 1998;17(4):401-403.
26. Veal D, McKinnon B. Home care highlights [pamphlet]. *Vasc Access Devices.* 1993;1:3-4.
27. Sando K, Fujii M, Tanaka K, et al. Lock method using sodium hydroxide solution to clear occluded central venous access devices. *Clin Nutr.* 1997;16(4):185-188.
28. Crnich CJ, Halfmann JA, Crone WC, Maki DG. The effects of prolonged ethanol exposure on the mechanical properties of polyurethane and silicone catheters used for intravascular access. *Infect Control Hosp Epidemiol.* 2005;26(8):708-714.
29. Gorski LA. Central venous access device occlusions: part 1: thrombotic causes and treatment. *Home Healthc Nurse.* 2003;21(2):115-121.
30. Gilmore J. KDOQI clinical practice guidelines and clinical practice recommendations—2006 updates. *Nephrol Nurs J.* 2006;33(5):487-488.
31. Moureau NL, Thompson McKinnon B, Douglas CM. Multidisciplinary management of thrombotic catheter occlusions in vascular access devices. *J Vasc Access Device.* 1999;4(2):22-29.
32. Andris DA, Krzywda EA, Schulte W, Ausman R, Quebbeman EJ. Pinch-off syndrome: a rare etiology for central venous catheter occlusion. *J Parenter Enteral Nutr.* 1994;18(6):531-533.