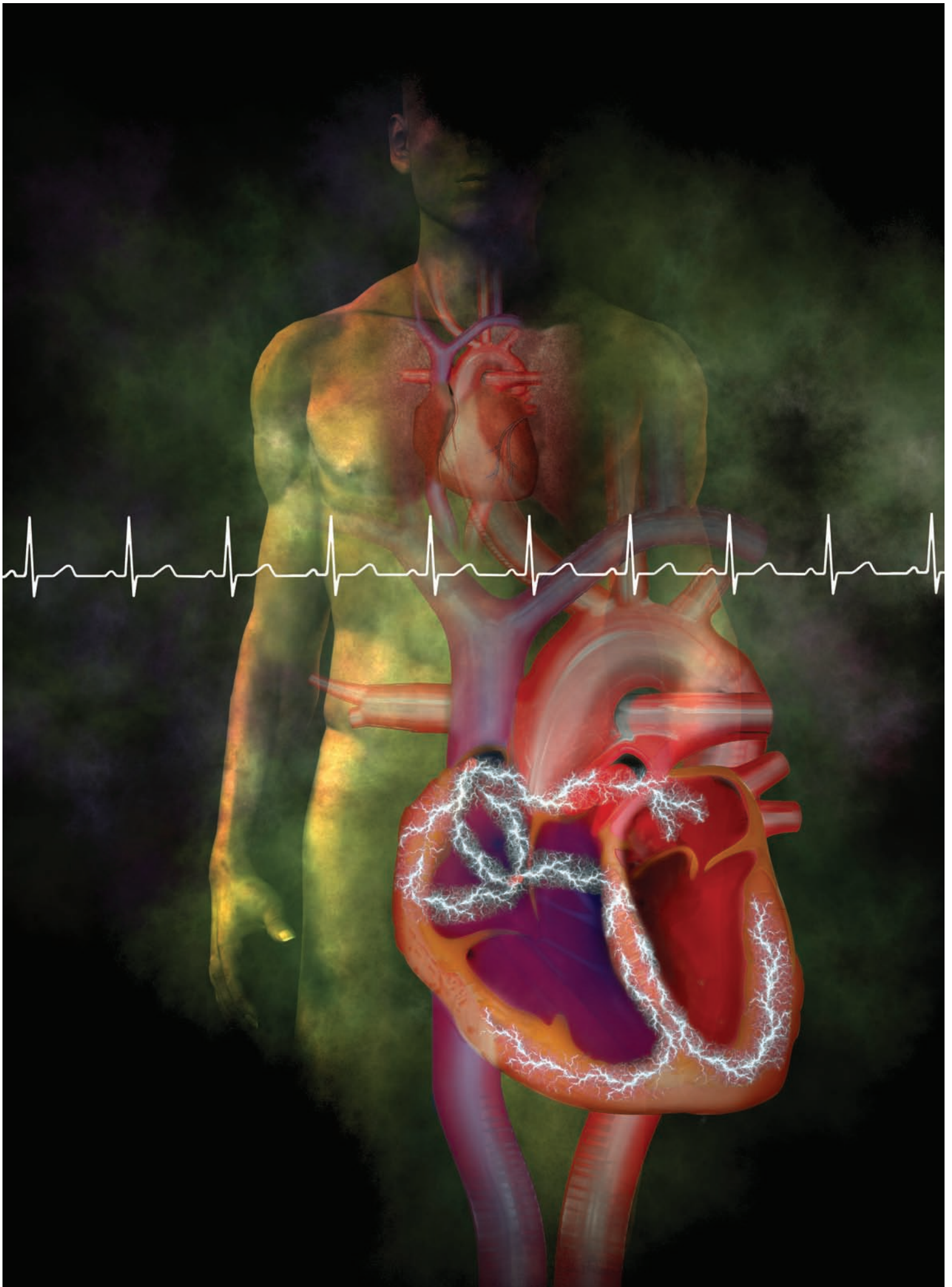

**2.3**ANCC  
CONTACT HOURS

# 12-lead ECGs

## PART II: IDENTIFYING COMMON ABNORMALITIES

By Guy Goldich, MSN, RN, CCRN

NURSES WHO CAN independently interpret an ECG can prepare to intervene appropriately and assist with emergency care the patient may need. Last month, the first part of this article discussed the basics of ECG interpretation. This article explains some advanced techniques that nurses can use to interpret common ECG abnormalities: bundle-branch blocks, myocardial infarction (MI), and common dysrhythmias.

### **Bundle-branch blocks: Obstruction in the conduction**

Probably the most common ECG abnormality nurses encounter is a bundle-branch block, which appears on the ECG as a wider-than-normal QRS complex (0.12 second or more in duration). Originating in the sinoatrial (SA) node, the cardiac electrical impulse (action potential) normally travels to the atrioventricular node through the bundle of His into the right and left bundle branches in the septum. The two bundle branches terminate in the Purkinje fibers. When the impulse reaches them, ventricular depolarization begins.

Normally the impulse is delivered to myocardial cells on both sides of the heart simultaneously, so depolarization begins at the same time on both sides of the heart. The result is a very fast, synchronous contraction of the ventricles. On the ECG, the normal QRS complex duration from two intact bundle branches is less than 0.12 second (fewer than three small squares of the ECG paper).

A bundle-branch block occurs when one of the two bundle branches can't conduct the cardiac impulse to the myocardial cells. The most common reason for chronic bundle-branch block is ischemic heart disease. When a coronary artery supplying the bundle branch becomes stenotic, the flow of oxygenated blood is reduced and the bundle branch can't conduct impulses normally.

A common cause of acute bundle-branch block is acute MI. If the MI involves the ventricular septum, one of the bundle branches may become infarcted, leading to a loss of conduction. Although uncommon, physical injury of a bundle branch during an invasive procedure such as cardiac

catheterization or cardiac surgery is another possible cause of bundle-branch block.<sup>1</sup>

- In a **right bundle-branch block (RBBB)**, impulse conduction to the right ventricle is blocked. The electrical impulse is conducted only to the left side of the heart where left ventricular depolarization begins. The right side of the heart depolarizes only in response to the cell-to-cell wave of depolarization that travels from the left side of the heart. This cell-to-cell depolarization is much slower than the normal

synchronous depolarization; that's why the QRS complex is significantly wider than normal.

Examine lead  $V_1$  to identify a RBBB. In lead  $V_1$ , the normal QRS complex consists of a small R wave, then a large S wave. As you recall, lead  $V_1$  looks at the right side of the heart. A small vector originating in the septum toward  $V_1$  creates a small upward R wave; then the predominant mean QRS vector creates the large S wave as the mean QRS vector flows away from lead  $V_1$ .

In RBBB, the path of the mean QRS vector is changed due to left-to-right slow conduction; lead  $V_1$  now records a delayed R wave approaching it, resulting in a positive R wave. So the key identifier of RBBB in lead  $V_1$  is a QRS complex wider than 0.12 second with a delayed (longer than 0.07 second) positive main R wave. Some RBBBs may display a triphasic waveform ("rabbit ears") consisting of a small R wave, downward S wave, and a second, larger R wave.<sup>2</sup>

- In a **left bundle-branch block (LBBB)**, electrical impulses don't reach the left side of the heart normally, so once again, synchronous depolarization of the ventricles doesn't occur. Depolarization begins in the right side of the heart and travels in a right-to-left direction via slow cell-to-cell depolarization. Lead  $V_1$  records the mean QRS vector directed away from its positive lead, resulting in a wide downward complex. Because the mean vector takes a relatively longer time to cross to the left side of the

heart, the QRS complex is wider than 0.12 second. The key to recognizing a LBBB is a wide, downward S wave or rS wave in leads  $V_1$  and  $V_2$ .

## Recognizing an MI

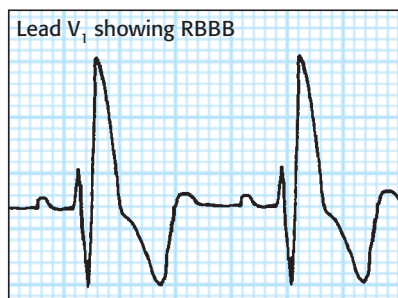
One of the most critical functions of the 12-lead ECG is to determine whether a patient is experiencing an acute MI. A series of predictable ECG changes that occur during an MI help clinicians identify it quickly and initiate appropriate treatment.

Among one of the earliest changes in the ECG tracing is an elevation of the ST segment, indicating reversible myocardial injury (see *Understanding ST-segment elevation*). In a normal ECG, the ST segment is level with the tracing's baseline (isoelectric). When myocardial cells sustain injury from MI, depolarization is impaired, resulting in ST-segment elevation in the leads monitoring the affected areas of the heart. An ST-segment-elevation MI (STEMI), the most serious type of MI, is associated with more complications and a higher risk of death.<sup>3</sup>

The leads with ST-segment elevations identify the area of myocardial injury, so a nurse can determine the region of the heart affected if he or she knows which area is monitored by which ECG lead. Let's look at some examples.

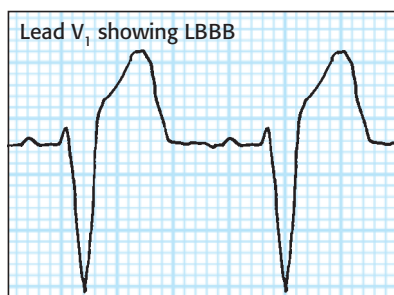
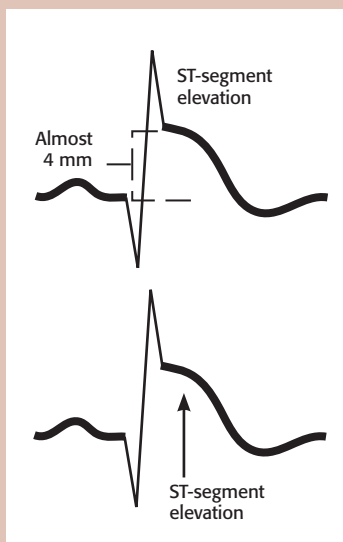
- Because leads II, III, and aVF all monitor the inferior (or bottom) wall of the heart from slightly different directions, they're usually described as the inferior leads. This area of the heart is perfused by the right coronary artery (see *Going with the flow*). A patient with a STEMI involving the inferior wall of the heart will have elevated ST segments in leads II, III, and aVF (see *Inferior-wall STEMI*).

A posterior-wall MI, which may be difficult to diagnose on a 12-lead ECG, may accompany an inferior-wall and/or lateral-wall MI. If a posterior-wall MI is suspected, the healthcare

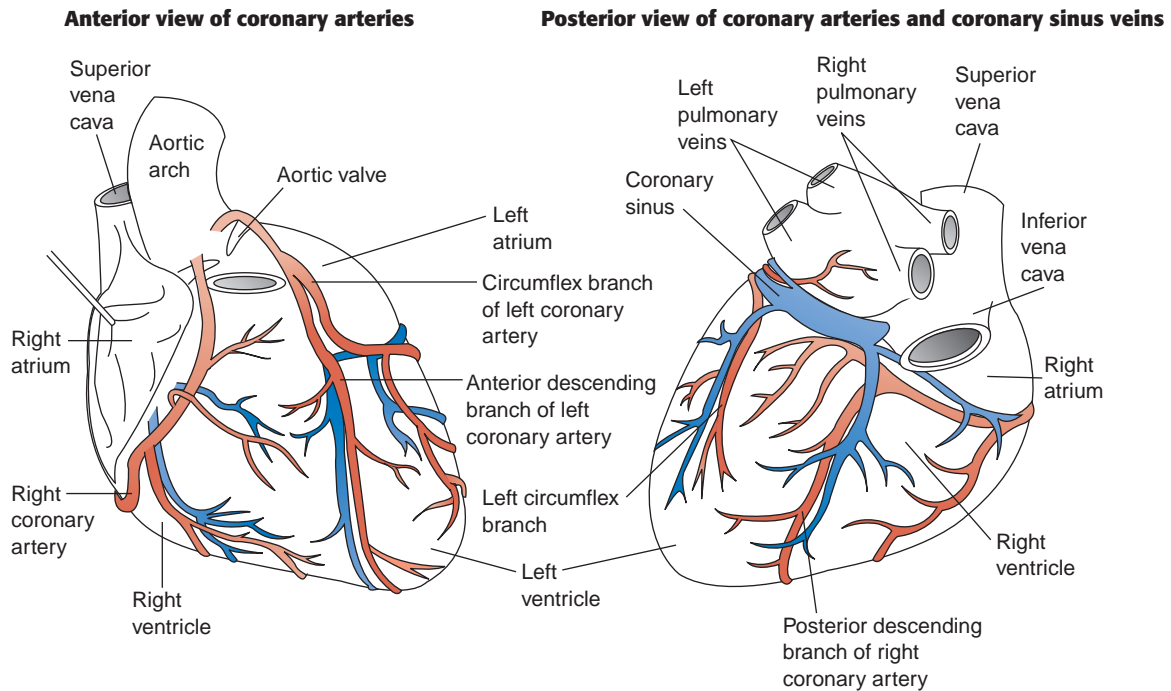


## Understanding ST-segment elevation

Impaired depolarization secondary to myocardial injury causes ST-segment elevation in the leads monitoring the injured areas of the heart.

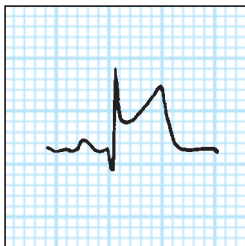

## Going with the flow

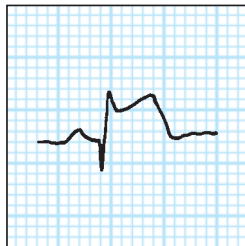


### Inferior-wall STEMI

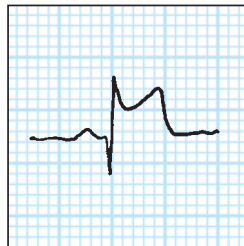Lead II



Lead III

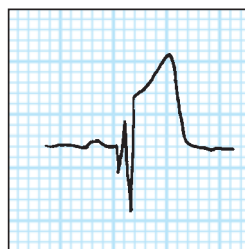


Lead aVF

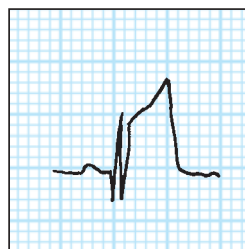


### Anterior-wall STEMI

Lead V<sub>3</sub>



Lead V<sub>4</sub>



provider will examine a posterior lead ECG (leads V<sub>7</sub> to V<sub>9</sub>), which is beyond the scope of this article.<sup>4</sup>

- Another common infarct lead pattern occurs when an MI involves the interventricular septum, which is perfused by the left anterior descending (LAD) coronary artery. In a *septal MI*, the leads monitoring the septum's electrical activity will display elevated ST segments. Precordial (chest) leads V<sub>1</sub> and V<sub>2</sub>, which are located on the anterior chest wall directly over the septum, most accurately monitor the septum's electrical activity. (These leads also are known as the septal leads.) The patient experiencing a septal MI will have ST-segment elevations in leads V<sub>1</sub> and V<sub>2</sub>.

- Directly to the left of the septal area of the heart is the large frontal or *anterior* wall of the heart, which is also perfused by the LAD coronary artery. As the most muscular and powerful pumping wall of the heart, the



anterior wall is responsible for a large proportion of cardiac output. Anatomically, leads  $V_3$  and  $V_4$  are located directly above the anterior wall of the heart and monitor its electrical activity. An anterior-wall STEMI will cause the ST segments in these leads to be elevated (see *Anterior-wall STEMI*).

- The heart's lateral wall, perfused by the left circumflex artery, is located to the left of the anterior wall and follows the curve of the left lateral chest wall. Relatively muscular, it also contributes significantly to the heart's pumping ability. The ECG lead pattern that monitors the lateral wall's electrical activity is more complex because the lateral wall is monitored by a combination of precordial (chest) leads and frontal (limb) leads.

Chest leads  $V_5$  and  $V_6$  are located on the left lateral chest wall and monitor electrical activity by looking down at the lateral heart wall. Leads I and aVL also monitor the lateral wall's electrical activity. A patient with a lateral-wall STEMI will have ST-segment elevations in leads I, aVL,  $V_5$ , and  $V_6$ .

Although an MI can affect a single heart wall, such as a discrete septal MI or anterior-wall MI, in some cases the area of infarction involves more than one area of the heart. In such a case, ST-segment elevations appear in the leads monitoring all of the involved areas. For example, if the infarction extends into both the septum and the anterior wall, the ST-segment elevations would appear in leads  $V_1$ ,  $V_2$ ,  $V_3$ , and  $V_4$ . The areas involved in the MI are reflected by the descriptive name; in this case, an *anteroseptal* MI. For a look at how MI affects heart muscle, see *Tissue damage after MI*.

### Identifying common dysrhythmias

When assessing for cardiac rhythm abnormalities on the ECG, treat the patient, not the monitor. If an abnormal rhythm or rhythm change appears, assess the patient and document level of consciousness, vital signs, chest pain, shortness of breath, and other signs and symptoms associated with the dysrhythmia. Use your assessment skills, nursing

judgment, and knowledge of ECGs to determine the level of urgency.

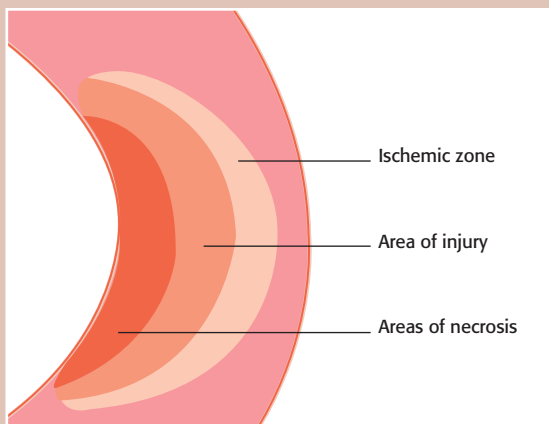
- **Sinus bradycardia** is a sinus rhythm slower than the lower normal sinus rate of 60 beats/minute. The P waves, QRS complexes, and T waves are all normal. Sinus bradycardia is commonly caused by ischemic heart disease that causes the SA node to malfunction.

Sinus bradycardia can also be caused by acute MI and some types of medications, such as beta-blockers. Well-conditioned athletes may have normal resting heart rates slower than 60 beats/minute. Assess the patient for hemodynamic stability if a new or profound sinus bradycardia develops and contact the healthcare provider if the patient is symptomatic. Signs and symptoms that may accompany sinus bradycardia include hypotension, lethargy, fatigue, chest discomfort, and difficulty breathing. Be prepared to follow the American Heart Association (AHA) Advanced Cardiovascular Life Support (ACLS) guidelines.

- **Sinus tachycardia** is a sinus rhythm that's faster than the upper normal sinus rate of 100 beats/minute. Sinus tachycardia can produce heart rates of 100 to 150 beats/minute. At faster rates, the heart's myocardial oxygen demand increases, and a patient with preexisting heart disease may experience chest discomfort or other signs and symptoms. Sinus tachycardia usually is related to a physiologic cause, such as fever, infection, pain, physical exertion, anxiety, hypoxia, or shock.<sup>5</sup> If the cause is identified and treated, the heart rate usually decreases. To manage sinus tachycardia with an unknown cause, the healthcare provider may prescribe a beta-blocker such as metoprolol or atenolol.

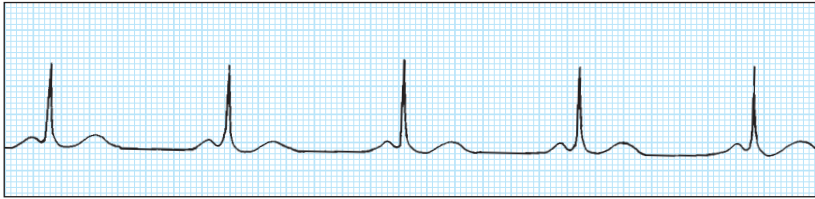
- **Atrial fibrillation (AF)**, one of the most common dysrhythmias encountered in clinical practice, has two predominant characteristics: an irregularly irregular heart rhythm and no discernible P waves. Normally, after passive ventricular filling, the atria contract regularly and eject their load of blood into the ventricles (atrial kick). In AF, atrial kick is lost. Instead of contracting normally, the atria quiver due to random and chaotic depolarization

### Tissue damage after MI

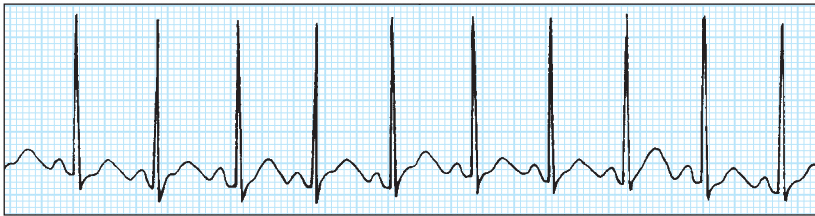

After an MI, the heart muscle has three zones of damage. Necrotic tissue dies from lack of blood flow. Injured cells may recover and ischemic cells can be saved if the area is reperfused promptly.

#### Sinus bradycardia



#### Sinus tachycardia



of atrial cells. The random atrial depolarization is also responsible for the irregular ventricular rate, which can vary from 40 to 180 beats/minute. AF has many causes, including atrial enlargement from chronic obstructive pulmonary disease or other lung disease, thyroid disease, ischemic heart disease, acute MI, stress or fatigue, and excessive use of caffeine, alcohol, or cigarettes.

AF may be detected first during a routine vital signs check. If the patient has a new irregular heart rate or an abnormally fast or slow heart rate, obtain a 12-lead ECG and look for an irregularly irregular rhythm and fibrillation (f) waves, the two hallmarks of AF. Perform a thorough physical assessment because patients can rapidly become hemodynamically unstable or develop worsening heart failure. If the patient has unstable or symptomatic AF, follow AHA ACLS guidelines. If the patient is stable, the healthcare provider may order oral medications to control or convert AF, such as metoprolol, diltiazem, digoxin, or amiodarone.

All patients with AF lasting more than 48 hours are at high risk for thrombus formation because of irregular blood flow in the atria. If released into the circulation, these

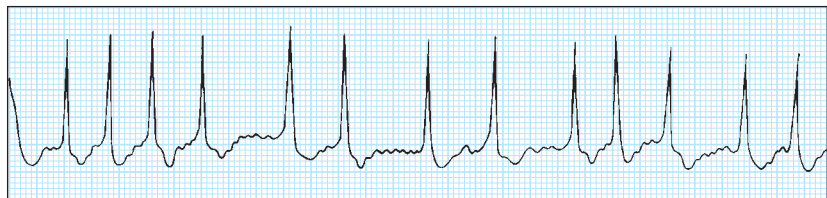
thrombi can cause arterial occlusion resulting in life-threatening complications such as stroke. As prescribed, administer I.V. heparin and start the patient on oral warfarin to prevent thromboembolism.<sup>6</sup>

Several new novel oral anticoagulants are now available, such as dabigatran and rivaroxaban. These

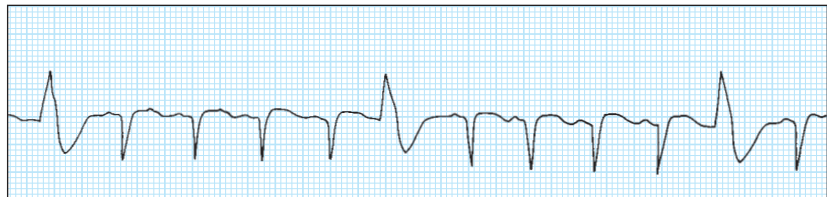
medications don't require periodic blood tests to determine the level of anticoagulation.<sup>7</sup>

• **Premature ventricular contractions (PVCs)** are characterized by a wide, abnormal QRS complex because conduction occurs through the ventricular tissue and not the His-Purkinje system. Look for a QRS greater than 0.12 second that appears large, abnormal, and premature (occurring *before* the next sinus beat). Caused by irritable ventricular tissue that depolarizes early and unpredictably, PVCs can be triggered by heart failure, electrolyte imbalances, stimulants such as caffeine, hypoxia, acute MI, mitral valve prolapse, and thyroid disease. Rare or isolated PVCs seldom require aggressive treatment. However, if you notice that the frequency of PVCs is increasing, or if you see new groups or "runs" of PVCs, contact the healthcare provider for further evaluation.

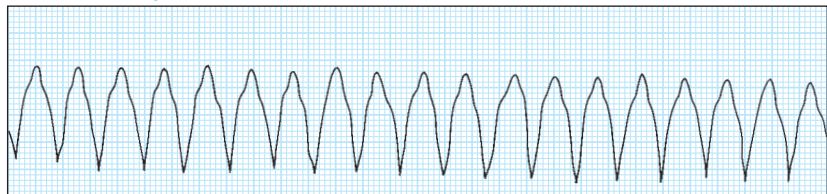
#### Atrial fibrillation



#### Isolated PVCs



#### Ventricular tachycardia



• **Ventricular tachycardia (VT)** is a very rapid (100 to 250 beats/minute) series of wide-complex ventricular depolarizations. In this dysrhythmia, abnormal ventricular tissue rapidly depolarizes, taking rhythm control away from the sinus node. Along with the rapid rate, VT is characterized by wide, bizarre QRS complexes usually followed by large T waves in a direction opposite to the major QRS deflection.

If the patient is unresponsive, apneic, and pulseless, call a code and start CPR. If the patient has a pulse and is awake, treat this situation as a medical emergency. Call a rapid response team, bring a crash cart with a monitor/defibrillator to the bedside, and follow AHA ACLS guidelines

### Summing up

Like any new skill, interpreting 12-lead ECGs takes practice and

commitment. Nurses can improve their expertise by making a habit of reviewing their patients' ECGs routinely and seeking guidance from colleagues experienced in ECG interpretation, such as senior clinical nurses, clinical nurse specialists, and clinical nurse educators. Many physicians and other healthcare providers are also happy to review ECGs with nurses who are interested in learning to spot problems early. With practice and experience, nurses can make ECG interpretation a valuable nursing tool that helps them recognize complications promptly and intervene appropriately. ■

#### REFERENCES

1. Kaplow R, Adams D. Postoperative dysrhythmias. In: Hardin SR, Kaplow R, eds. *Cardiac Surgery Essentials for Critical Care Nursing*. Sudbury, MA: Jones & Bartlett; 2010.
2. Lough ME, Thompson C. Cardiovascular diagnostic procedures. In: Urden LD, Stacy KM, Lough ME, eds. *Critical Care Nursing*, 7th ed. St. Louis: Mosby; 2010.

3. Topol E. *Textbook of Interventional Cardiology*. Philadelphia, PA: W.B. Saunders; 2008.
4. van Gorselen EOF, Verheugt FWA, Meursing BTJ, Oude Ophuis AJM. Posterior myocardial infarction: the dark side of the moon. *Neth Heart J*. 2007;15(1):16-21.
5. Perin KQ, MacLeod CE. *Understanding the Essentials of Critical Care Nursing*. Upper Saddle River, NJ: Pearson; 2013.
6. January CT, Wann LS, Alpert JS, et al. 2014 AHA/ACC/HRS guideline for the management of patients with atrial fibrillation: executive summary: a report of the American College of Cardiology/American Heart Association task force on practice guidelines and the Heart Rhythm Society. *J Am Coll Cardiol*. [e-pub March 28, 2014].
7. Spinler SA, Shafir V. New oral anticoagulants for atrial fibrillation. *Circulation*. 2012;126(1):133-137.

Guy Goldich is course coordinator and instructor at Abington (Pa.) Memorial Hospital's Dixon School of Nursing.

This article, which has been adapted and updated, originally appeared in the December issue of *Nursing2006*.

The author and planners have disclosed no potential conflicts of interest, financial or otherwise.

DOI-10.1097/01.NURSE.0000452990.26288.b4

> For more than 13 additional continuing education articles related to diagnostic tools, go to [NursingCenter.com/CE](http://NursingCenter.com/CE). <



**Earn CE credit online:**  
Go to <http://www.nursingcenter.com/CE/nursing> and receive a certificate within minutes.

#### INSTRUCTIONS

### 12-lead ECGs part II: Identifying common abnormalities

#### TEST INSTRUCTIONS

- To take the test online, go to our secure website at <http://www.nursingcenter.com/ce/nursing>.
- On the print form, record your answers in the test answer section of the CE enrollment form on page 37. Each question has only one correct answer. You may make copies of these forms.
- Complete the registration information and course evaluation. Mail the completed form and registration fee of \$21.95 to: **Lippincott Williams & Wilkins, CE Group**, 74 Brick Blvd., Bldg. 4, Suite 206, Brick, NJ 08723. We will mail your certificate in 4 to 6 weeks. For faster service, include a fax number and we will fax your certificate within 2 business days of receiving your enrollment form.
- You will receive your CE certificate of earned contact hours and an answer key to review your results. There is no minimum passing grade.
- Registration deadline is September 30, 2016.

#### DISCOUNTS and CUSTOMER SERVICE

- Send two or more tests in any nursing journal published by Lippincott Williams & Wilkins together by mail, and deduct \$0.95 from the price of each test.
- We also offer CE accounts for hospitals and other healthcare facilities on [nursingcenter.com](http://nursingcenter.com). Call **1-800-787-8985** for details.

#### PROVIDER ACCREDITATION

Lippincott Williams & Wilkins, publisher of *Nursing2014* journal, will award 2.3 contact hours for this continuing nursing education activity.

Lippincott Williams & Wilkins is accredited as a provider of continuing nursing education by the American Nurses Credentialing Center's Commission on Accreditation.

Lippincott Williams & Wilkins is also an approved provider of continuing nursing education by the District of Columbia and Florida #50-1223. This activity is also provider approved by the California Board of Registered Nursing, Provider Number CEP 11749 for 2.3 contact hours.

Your certificate is valid in all states.