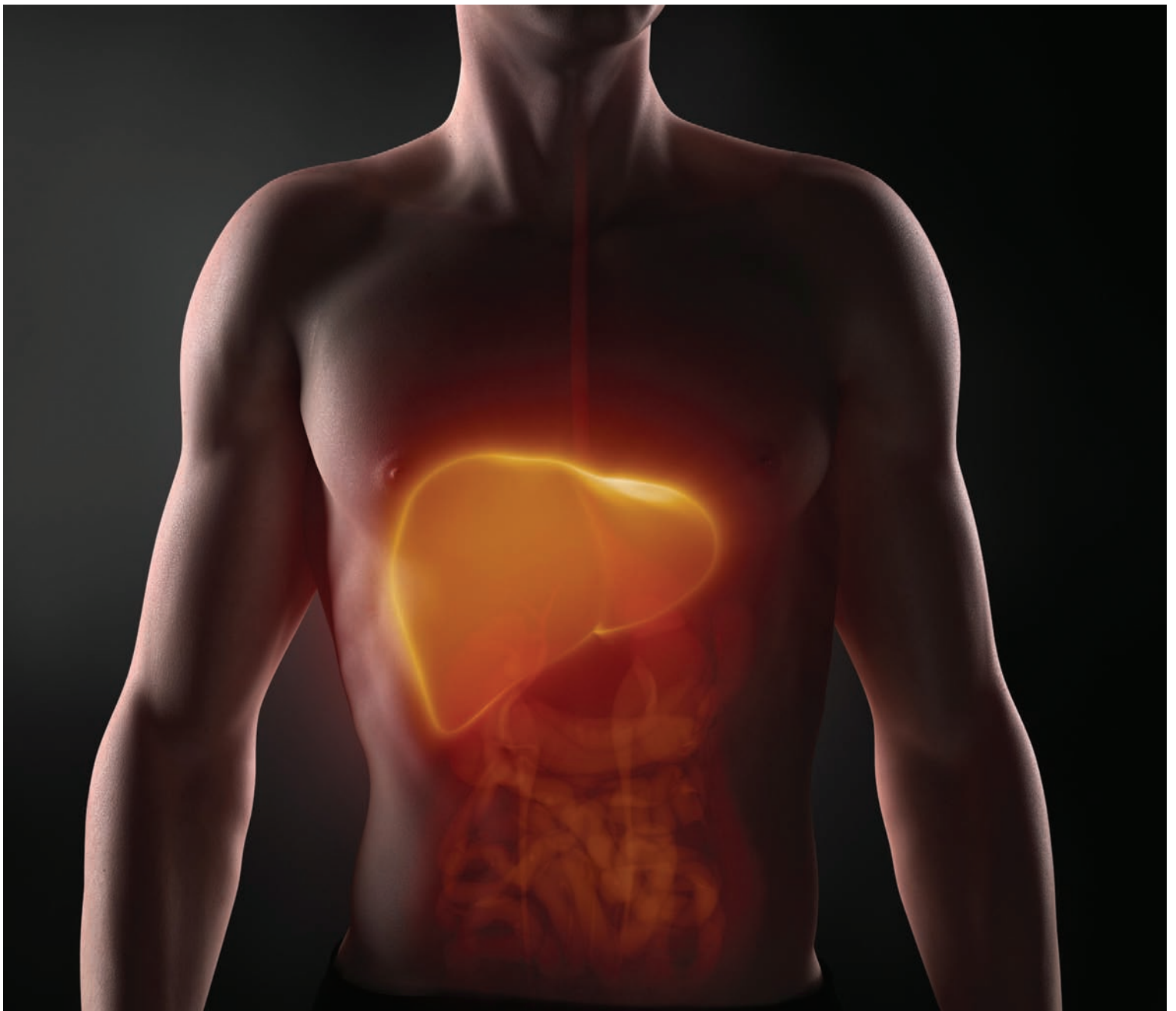


# Autoimmune hepatitis

When your patient's liver is the “enemy”





**2.3**  
ANCC  
CONTACT HOURS

## Learn how to distinguish the unique features of autoimmune hepatitis from other types of the disease.

By Richard L. Pullen, Jr., EdD, MSN, RN, CMSRN, and Jeanette M. Embrey, PhD, MS, RN-BC

Autoimmune hepatitis (AIH) affects 100,000 to 200,000 people in the United States, accounting for 6% of liver transplants, according to the National Digestive Diseases Information Clearinghouse. It's a form of hepatitis in which an individual's immune system attacks his or her liver.

Approximately 78% of those with AIH are women, and it occurs in all ethnic groups. The frequency of AIH among patients with chronic liver disease in North America is between 11% and 23%. Without treatment, AIH can lead to cirrhosis, liver failure, and death.

In this article, we'll discuss the management of a patient with AIH.

### Hepatitis review

Regardless of the underlying cause, hepatitis can affect the liver's ability to carry out vital functions, including controlling and storing proteins, fats, carbohydrates, vitamins, and minerals; making proteins and clotting factors; and producing bile. The liver also regulates hormones and filters poisons, bacteria, toxins, and medications from the blood.

The word *hepatitis* is a general term that refers to any inflammation of the liver caused by many underlying pathologies. Inflammation is followed by a disruption in normal blood flow through the liver (ischemia), leading to necrosis.

Hepatitis is most frequently caused by a virus, particularly hepatitis A virus (HAV), hepatitis B virus (HBV), and hepatitis C virus (HCV). Although HAV is generally self-limiting and has a good prognosis, HBV and HCV—affecting 1.2 million and 3.2 million Americans, respectively—may progress to hepatic fibrosis (scarring), especially without aggressive treatment.

Fibrosis is a mechanism for the liver to repair itself from the effects of inflammation. However, depending on the stage, fibrosis may further impair blood flow through the liver, leading to cirrhosis, which occurs when there's excessive scarring that reduces blood supply, resulting in liver failure.

Nonviral causes of hepatitis include non-alcoholic fatty liver disease, alcoholic hepatitis, toxin-induced hepatitis, drug-induced hepatitis, and AIH. Viral and nonviral causes of hepatitis can lead to fibrosis, cirrhosis, and liver failure, increasing the patient's risk of hepatic carcinoma.

Let's take a closer look at AIH, which is caused by an overactive immune system.

### How it happens

AIH is a disease in which a person's own immune system attacks liver cells, leading to inflammation. The immune system overacts and the body incorrectly identifies the liver as foreign (not belonging to the body). When this occurs, the immune system produces protective antibodies (autoantibodies) that attack the "enemy" organ. AIH may coexist with other autoimmune disorders (see *Diseases associated with AIH*).

Certain human leukocyte antigens (HLAs) found on chromosome number 6 may predispose a person to AIH. These antigens are HLA-DR3 and HLA-DR4. Researchers posit that a cascade of T cell-mediated events is triggered in AIH, leading to progressive inflammation and fibrosis of the liver.

The measles virus, hepatitis viruses, cytomegalovirus, and Epstein-Barr virus may be potential triggers in genetically predisposed individuals. However, these suspected triggers remain controversial among researchers,

and the evidence implicating hepatitis viruses is weak.

Some medications, including, but not limited to, methyldopa, isoniazid, and phenytoin, and some herbs can cause liver injury that mimics AIH.

### Typecast

AIH is classified as type 1, type 2, or type 3.

- **Type 1** is the most common form of AIH and can occur at any age. About 50% of these patients have other autoimmune diseases. It's characterized by two autoantibodies: antinuclear antibody (ANA) and smooth muscle antibody (SMA).
- **Type 2** is most common among young women and girls, and often occurs with other autoimmune disorders. Patients with type 2 AIH have the liver kidney microsomal antibody.
- **Type 3** is diagnosed when a patient doesn't initially present with autoantibodies but may have other histologic (liver biopsy) or lab evidence and signs and symptoms that meet

the criteria for a diagnosis of AIH. This occurs in about 20% of patients with AIH, who usually develop autoantibodies during the course of the disease.

### Signs and symptoms checklist

The onset of AIH most often begins with insidious symptoms, such as fatigue, joint aches, loss of appetite, and malaise. In fact, these symptoms may be so subtle that the patient doesn't seek medical care. Some individuals only experience a vague feeling of abdominal discomfort; however, increasing fatigue, the onset of jaundice, and changes in stool color are the most common reasons for seeking medical care in 80% of AIH cases.

Jaundice arises late and may follow several months of nonspecific symptoms. The jaundice phase includes yellowing of the eyes (sclera), mucous membranes, and skin; dark urine; and light to pale color stools. It correlates with a rising serum bilirubin level. As the disease progresses, the serum albumin level may decrease as the serum bilirubin rises.

The patient may also experience a low-grade fever, nausea, muscle aches and pains, and abdominal discomfort and/or pain. Jaundice tends to cause itching because of bile salts on the skin. Enlargement of the liver (hepatomegaly) may or may not be present, especially in the early stages of AIH.

### Assessing AIH

The only way to differentiate one type of hepatitis from another is through lab analysis and liver biopsy—the gold standard for a diagnosis of AIH.

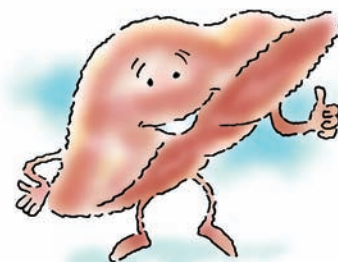Increased serum globulins (protein), the presence of autoantibodies, negative viral hepatitis markers, and increased liver enzymes point toward a diagnosis of AIH. In fact, severe AIH usually, but not always, results in alanine aminotransferase (ALT) and aspartate transaminase (AST) levels 7 to 10 times the upper limit of normal (see *Assessing selected liver function tests*).

A liver biopsy is essential for a diagnosis of AIH. A classic finding in AIH is *interface*

### Diseases associated with AIH

- Primary biliary cirrhosis
- Primary sclerosing cholangitis
- Inflammatory bowel disease
- Celiac disease
- Systemic sclerosis (scleroderma)
- Rheumatoid arthritis
- Mixed connective tissue disease
- Sjögren syndrome
- SLE
- Fibrosing alveolitis
- Glomerulonephritis
- Hemolytic anemia
- Thyroiditis
- Diabetes
- Psoriasis
- Vitiligo
- Uveitis
- Polymyositis
- Multiple sclerosis
- Myasthenia gravis
- Mononeuritis multiplex
- Antiphospholipid antibody syndrome





## Assessing selected liver function tests

Liver function test	Reference range*	Considerations
ALT	30 to 65 U/L	<ul style="list-style-type: none"> <li>Marked elevations indicate viral hepatitis, AIH, drug- and/or medication-induced liver injury, alcohol-induced liver disease, heart disease, liver tumor, or ischemic injury to the liver secondary to shock.</li> </ul>
AST	15 to 37 U/L	<ul style="list-style-type: none"> <li>An AST to ALT ratio of greater than 2 suggests alcoholic liver disease.</li> <li>A return of normal values indicates an improvement in liver function or end-stage liver disease.</li> </ul>
ALP	50 to 136 U/L	<ul style="list-style-type: none"> <li>Marked elevations indicate nonalcoholic fatty liver disease, alcoholic liver disease, biliary cirrhosis, cholelithiasis, or liver tumors.</li> <li>If ALT predominates over ALP, consider hepatocellular damage.</li> <li>If ALP predominates over ALT, suspect gallbladder injury; marked elevations of both indicate a combination of hepatocellular and gallbladder injury.</li> <li>A return of normal values indicates an improvement in liver function or end-stage liver disease.</li> </ul>
Total bilirubin	0.2 to 1 mg/dL	<ul style="list-style-type: none"> <li>Suspect liver injury if the bilirubin is greater than two times the upper limit of normal and if ALT or AST is elevated.</li> <li>Assess for jaundice, especially when levels rise above 3 mg/dL.</li> </ul>
Albumin	3 to 5 g/dL	<ul style="list-style-type: none"> <li>When the liver becomes damaged, it loses its ability to make albumin; bleeding may also occur when albumin is low.</li> <li>Correlate levels with serum platelets, complete blood cell count, international normalized ratio, and partial thromboplastin time.</li> <li>Assess for edema and ascites when albumin is very low.</li> </ul>

\*Values are based on the reference ranges in one lab.

*hepatitis*—the infiltration of lymphocytes and plasma cells that causes inflammation throughout the hepatic parenchyma (bulk of the functioning liver) to the portal tracts (connective tissue containing branches of the portal vein and hepatic artery that bring blood to the sinusoids). Interface hepatitis may also occur in liver injury induced by drugs or viruses; however, some differences exist. For example, severe portal inflammation, prominent plasma cells, and fibrosis differentiate AIH from drug- and/or medication-induced hepatitis.

The liver biopsy also classifies the severity of fibrosis into five stages:

- stage 0—no fibrosis
- stage 1—mild fibrosis
- stage 2—moderate fibrosis
- stage 3—severe fibrosis, sometimes called *precirrhosis*
- stage 4—severe fibrosis with cirrhosis.

A diagnosis of AIH is based on a careful evaluation of histologic (liver biopsy) findings,

abnormal levels of serum globulins (proteins), the presence of autoantibodies and elevated liver enzymes, and patient history. Patient assessment includes an evaluation of preexisting physical conditions, medications, and social history of alcohol consumption, use of illicit drugs, and any exposure to blood and body fluids of others.

The International Autoimmune Hepatitis Group diagnostic criteria are used to establish a diagnosis of AIH. Simplified scoring criteria are also used by some healthcare professionals to diagnosis AIH. However, this simplified scoring needs more evidence-based research to ensure that it measures the scope of symptoms to establish a definitive diagnosis of AIH.

## Management matters

The goal of treatment is to stop the body's attack on the liver by suppressing the immune system. The standard medication therapy for

AIH is the administration of corticosteroids, such as prednisone, and the steroid-sparing immunosuppressant azathioprine. Prednisone is gradually decreased over a period of 4 to 8 weeks in parallel to an improvement of liver enzymes. Caution is necessary with the use of azathioprine because it can cause hepatotoxicity (see *Standard first-line medication therapy for AIH*). Other medications that may be used include the second-

generation corticosteroid budesonide and the steroid-sparing immunosuppressant mycophenolate mofetil (MMF).

It's imperative to ensure that the patient's symptoms result from AIH and not viral hepatitis before starting treatment. For example, if a patient is suspected of having AIH but he or she actually has viral hepatitis, the administration of prednisone will harm the patient by increasing viral replication. On the

## Standard first-line medication therapy for AIH

Medication	Adverse reactions	Nursing interventions
Prednisone	<ul style="list-style-type: none"> <li>• Insomnia</li> <li>• Nervousness</li> <li>• Increased appetite</li> <li>• Indigestion</li> <li>• Lightheadedness</li> <li>• Headache</li> <li>• Hirsutism</li> <li>• Hyperglycemia</li> <li>• Arthralgia</li> <li>• Cataracts</li> <li>• Glaucoma</li> <li>• Bleeding</li> <li>• Diaphoresis</li> <li>• Osteoporosis</li> <li>• Fractures</li> <li>• Hypertension</li> <li>• Muscle-wasting</li> <li>• Menstrual irregularities</li> <li>• Mental changes</li> <li>• Fluid retention</li> <li>• Weight gain</li> <li>• Infection</li> </ul>	<ul style="list-style-type: none"> <li>• Teach your patient to report weight gain, swelling of extremities, muscle weakness, black or tarry stools, fever, sore throat, colds, and infections.</li> <li>• Inform your patient that irritability, mood swings, and depression are common when taking steroids, especially at moderate-to-high doses for greater than 2 weeks. Melatonin can help with insomnia. Short-term mild sedatives and antidepressants may also be helpful.</li> <li>• Encourage your patient to eat a well-balanced, low-sodium diet. Vitamin D and calcium supplements help keep bones strong.</li> <li>• Encourage your patient to stay as active as possible.</li> <li>• Instruct your patient to take doses as prescribed and never decrease or stop taking the medication suddenly.</li> <li>• Encourage your patient to have routine eye exams.</li> <li>• Evaluate your patient's BP and lab values, including complete blood cell (CBC) count, blood glucose level, creatinine, and liver enzymes.</li> </ul>
Azathioprine	<ul style="list-style-type: none"> <li>• Fever</li> <li>• Chills</li> <li>• Bone marrow depression</li> <li>• Bleeding</li> <li>• Easy bruising</li> <li>• Anorexia</li> <li>• Nausea</li> <li>• Hepatotoxicity</li> <li>• Infection</li> <li>• Arthralgia</li> <li>• Rash</li> <li>• Malignancies</li> <li>• Infertility</li> </ul>	<ul style="list-style-type: none"> <li>• Instruct your patient to report any symptoms of infection and perform good hand hygiene.</li> <li>• Teach your patient to maintain good mouth care.</li> <li>• Teach your patient to protect the skin from trauma due to easy bruising.</li> <li>• Encourage your patient to limit exposure to light sources, which can cause various rashes and lesions and make the skin itch.</li> <li>• Encourage your patient to perform breast self-exams or testicular self-exams.</li> <li>• Encourage your patient to avoid alcohol and smoking.</li> <li>• Evaluate the CBC count for infection, and liver enzymes for hepatotoxicity.</li> </ul>





## did you know?

AIH was initially known as *lupoid hepatitis* in the 1950s because of its similarity to SLE. AIH has also been referred to in the literature as *chronic active hepatitis*.

other hand, if a patient is suspected of having viral hepatitis but he or she actually has AIH, the administration of antiviral agents places the patient at greater risk for liver failure.

AIH tends to be a chronic disorder that's characterized by periods of remission (symptoms controlled) and relapses (worsening of symptoms). However, AIH usually responds well to therapy. In fact, a patient's dramatic improvement with immunosuppressive therapy is one diagnostic feature of AIH. Approximately 80% of patients achieve remission within 18 months of starting therapy.

Early diagnosis and treatment is crucial to control inflammation and reduce fibrosis before the disease progresses to cirrhosis. The liver has an amazing ability to heal itself, especially in the early stages of fibrosis. It isn't likely that fibrosis will be reversed after cirrhosis is present. Cirrhosis can lead to portal hypertension, ascites, and hepatic encephalopathy. A liver transplant is the only option at this point to save the patient's life.

Let's take a look at a case study to illustrate the diagnosis and treatment of AIH.

## Case study

Our patient is a 54-year-old man with a 15-year history of systemic lupus erythematosus (SLE), which has manifested itself in the central nervous system, peripheral nervous system, and the patient's skin. Immunosuppressant medications were prescribed to keep the SLE under control. Liver enzymes were routinely monitored every 4 months to detect any changes in disease processes and/or toxic effects of medications, including azathioprine and MMF, on the liver.

Trended liver enzyme results over a 15-year period were generally within normal range, with occasional very slight elevations that quickly returned to normal in subsequent checkups. However, the ALT and AST values increased dramatically over a 4-week period, indicating an immune attack on the patient's liver.

The patient didn't feel ill as the immune attack unfolded, but did experience a vague

feeling of abdominal fullness that didn't prevent him from normal physical activities. He also experienced a 2-day episode of a "stomach bug" that included a low-grade fever and light-yellow color stools.

The patient returned to the rheumatologist within a few days of recovering from the "stomach bug" to recheck the liver enzymes—ALT was 127; AST, 59; and alkaline phosphatase (ALP), 137. He had no hepatomegaly or jaundice. A viral hepatitis profile and computed tomography (CT) scan of the abdomen were negative. Azathioprine (50 mg/day) was held to rule out any toxic effects of this medication on the liver, but MMF (1,000 mg/day) was continued.

Within a week, the ALT and AST levels critically increased to 3,345 U/L (50 X upper normal) and 1,100 U/L, respectively. The ALP level was only slightly elevated at 154 U/L. Serum bilirubin was increasing and serum albumin decreasing, indicating that severe liver damage was unfolding, which would likely lead to liver failure (see supplemental content on the *Nursing made Incredibly Easy!* iPad app).

The patient also had a positive test for ANA and C-reactive protein, and a decrease in serum complement—indicators of inflammation. Serum creatinine was increasing, which indicated that the inflammation was extending from the liver to the kidneys. The patient didn't feel or look ill, but was subsequently hospitalized.

A hepatologist joined the rheumatologist in the patient's care during the 4-day hospital stay. A repeat viral hepatitis profile was negative, and the patient's medication and social history were ruled out as possible causes for the elevated liver enzymes. A preliminary diagnosis of AIH was made.

It was thought that the patient's current immunosuppressive medications were causing the globulin levels to be depressed, whereas they're usually elevated in AIH. He underwent a CT-guided liver biopsy with procedural sedation. The pathology report showed extensive interface hepatitis with

prominent plasma cells, moderate-to-severe inflammation, and at least stage 2 fibrosis. The bile ducts weren't affected.

A final diagnosis was made: SLE-induced AIH. A diagnosis of AIH was atypical in this patient because of his gender and that he developed the disease while receiving immunosuppressant medications for SLE. The patient met the criteria for a definitive diagnosis of AIH before starting medication therapy (see supplemental content on the *Nursing made Incredibly Easy!* iPad app).

Additional immunosuppression was imperative to save the patient's liver from failing. The patient received an infusion of 1,000 mg of methylprednisolone, followed by prednisone (40 mg/day). The rheumatologist tapered the prednisone over several months to correlate with an improvement in liver enzymes. Increasing doses of azathioprine and MMF were included to allow a lower dose of prednisone. The patient was also placed on monthly infusions of belimumab, a monoclonal antibody that was approved by the FDA in 2011 specifically for the treatment of SLE (see supplemental content on the *Nursing made Incredibly Easy!* iPad app).

The patient will likely be on medication therapy for the rest of his life. The current regimen of low-dose prednisone with azathioprine and MMF is

working well. It's hopeful that the prednisone will be discontinued and a lower dose of azathioprine and MMF will maintain remission. A second liver biopsy may be performed at some point to determine if there's histologic improvement.

Receiving a diagnosis of AIH can cause your patient to experience shock, fear, frustration, and anxiety about the uncertainty of the disease. Depression may also occur as your patient attempts to cope with the disease and the effects of medications. Make sure you explain to your patient that prednisone can cause agitation, irritability, distraction, and insomnia and that azathioprine and prednisone also caused easy bruising. Tell your patient that he or she might gain weight while taking prednisone because it causes the body to conserve sodium that leads to fluid retention. The patient in our case study experienced these signs and symptoms, but he actually lost weight, which is atypical while on corticosteroid therapy.

Provide your patient with accurate information about AIH and all forms of hepatitis so he or she can teach others about the diagnosis. The education and nursing care you provide your patient will give him or her confidence to embrace the challenges of coping with chronic illness. The patient in our case report achieved remission in a relatively short time by adhering to the treatment regimen and working alongside his healthcare team.



### On the web

- **American Association for the Study of Liver Diseases:** <http://www.aasld.org/practiceguidelines/Documents/AIH2010.pdf>
- **American Liver Foundation:** <http://www.liverfoundation.org/abouttheliver/info/aihep>
- **Mayo Clinic:** <http://www.mayoclinic.com/health/autoimmune-hepatitis/DS00676>
- **National Digestive Diseases Information Clearinghouse:** <http://digestive.niddk.nih.gov/ddiseases/pubs/autoimmunehep>
- **U.S. National Library of Medicine:** [http://www.livertox.nih.gov/Phenotypes\\_auto.html](http://www.livertox.nih.gov/Phenotypes_auto.html)

### Unique disease, unique patients

Not all hepatitis is the same, so it's important to distinguish among the various types of hepatitis to manage your patient accurately and safely. Assessing the patient's health and social history, analyzing lab and imaging studies, and collaborating with an interprofessional healthcare team will promote safe care. Teach your colleagues about the similarities and differences among the various types of hepatitis. A diagnosis of AIH is a frightening experience for your patient. Offer him or her reassurance as you provide evidence-based nursing care. ■

## Learn more about it

American Liver Foundation. Autoimmune hepatitis. [http://www.liversociety.org/html/autoimmune\\_hepatitis.html](http://www.liversociety.org/html/autoimmune_hepatitis.html).

Czaja AJ. Difficult treatment decisions in autoimmune hepatitis. *World J Gastroenterol*. 2010;16(8):934-947.

Gacad V, Waller K. Cryptogenic hepatitis: a case study in autoantibody negative autoimmune hepatitis. *Clin Lab Sci*. 2011;24(4):196-201.

Gleeson D, Heneghan MA, British Society of Gastroenterology. British Society of Gastroenterology (BSG) guidelines for management of autoimmune hepatitis. *Gut*. 2011;60(12):1611-1629.

Invernizzi P, Mackay IR. Etiology of autoimmune hepatitis. *World J Gastroenterol*. 2008;14(21):3306-3312.

Kee JL. *Laboratory and Diagnostic Tests*. 9th ed. Upper Saddle River, NJ: Pearson Education, Inc.; 2013.

Lamers MM, Van Oijen MG, Pronk M, Drenth JP. Treatment options for autoimmune hepatitis: a systematic review of randomized controlled trials. *J Hepatol*. 2010;53(1):191-198.

Mackay IR. Autoimmune hepatitis: from the clinic to the diagnostic laboratory. *Lab Med*. 2011;42(4):224-233.

Makol A, Watt KD, Chowdhary VR. Autoimmune hepatitis: a review of current diagnosis and treatment. *Hepat Res Treat*. [E-pub ahead of print.]

Manns MP, Czaja AJ, Gorham JD, et al. Diagnosis and management of autoimmune hepatitis. *Hepatology*. 2010;51(6):2193-2213.

National Digestive Diseases Information Clearinghouse. Autoimmune hepatitis. <http://digestive.niddk.nih.gov/ddiseases/pubs/autoimmunehep/index.aspx>.

Palmer M. *Hepatitis and Liver Disease*. New York, NY: Avery Publishing, Co.; 2004.

Weiler-Normann C, Lohse AW. Autoimmune hepatitis: a life-long disease. *J Hepatol*. 2013;58(1):5-7.

Wolf DC. Autoimmune hepatitis treatment and management. <http://emedicine.medscape.com/article/172356-overview#0101>.

Yasui S, Fujiwara K, Yonemitsu Y, Oda S, Nakano M, Yokosuka O. Clinicopathological features of severe and fulminant forms of autoimmune hepatitis. *J Gastroenterol*. 2011;46(3):378-390.

At Amarillo College in Amarillo, Tex., Richard L. Pullen, Jr., is a Professor of Nursing and the Assistant Director of the ADN Program and Jeanette M. Embrey is an Assistant Professor of Nursing. Richard Pullen is also a *Nursing made Incredibly Easy!* Editorial Advisory Board Member.

The authors and planners have disclosed that they have no financial relationships related to this article.

DOI-10.1097/01.NME.0000438408.00131.de

For more than 6 additional continuing education articles related to immunology/allergy topics, go to [Nursingcenter.com/CE](http://Nursingcenter.com/CE).



**CE CONNECTION**

**Earn CE credit online:**

Go to <http://www.nursingcenter.com/CE/nmie> and receive a certificate *within minutes*.

### INSTRUCTIONS

#### Autoimmune hepatitis: When your patient's liver is the "enemy"

##### TEST INSTRUCTIONS

- To take the test online, go to our secure Web site at <http://www.nursingcenter.com/CE/nmie>.
- On the print form, record your answers in the test answer section of the CE enrollment form on page 56. Each question has only one correct answer. You may make copies of these forms.
- Complete the registration information and course evaluation. Mail the completed form and registration fee of \$21.95 to: Lippincott Williams & Wilkins, CE Group, 74 Brick Blvd., Bldg. 4, Suite 206, Brick, NJ 08723. We will mail your certificate in 4 to 6 weeks. For faster service, include a fax number and we will fax your certificate within 2 business days of receiving your enrollment form.
- You will receive your CE certificate of earned contact hours and an answer key to review your results. There is no minimum passing grade.
- Registration deadline is February 28, 2016.

##### DISCOUNTS and CUSTOMER SERVICE

- Send two or more tests in any nursing journal published by Lippincott Williams & Wilkins together by mail and deduct \$0.95 from the price of each test.
- We also offer CE accounts for hospitals and other health care facilities on nursingcenter.com. Call 1-800-787-8985 for details.

##### PROVIDER ACCREDITATION

Lippincott Williams & Wilkins, publisher of *Nursing made Incredibly Easy!*, will award 2.3 contact hours for this continuing nursing education activity.

Lippincott Williams & Wilkins is accredited as a provider of continuing nursing education by the American Nurses Credentialing Center's Commission on Accreditation.

This activity is also provider approved by the California Board of Registered Nursing, Provider Number CEP 11749 for 2.3 contact hours. Lippincott Williams & Wilkins is also an approved provider of continuing nursing education by the District of Columbia and Florida #FBN2454.

Your certificate is valid in all states.

The ANCC's accreditation status of Lippincott Williams & Wilkins Department of Continuing Education refers only to its continuing nursing educational activities and does not imply Commission on Accreditation approval or endorsement of any commercial product.