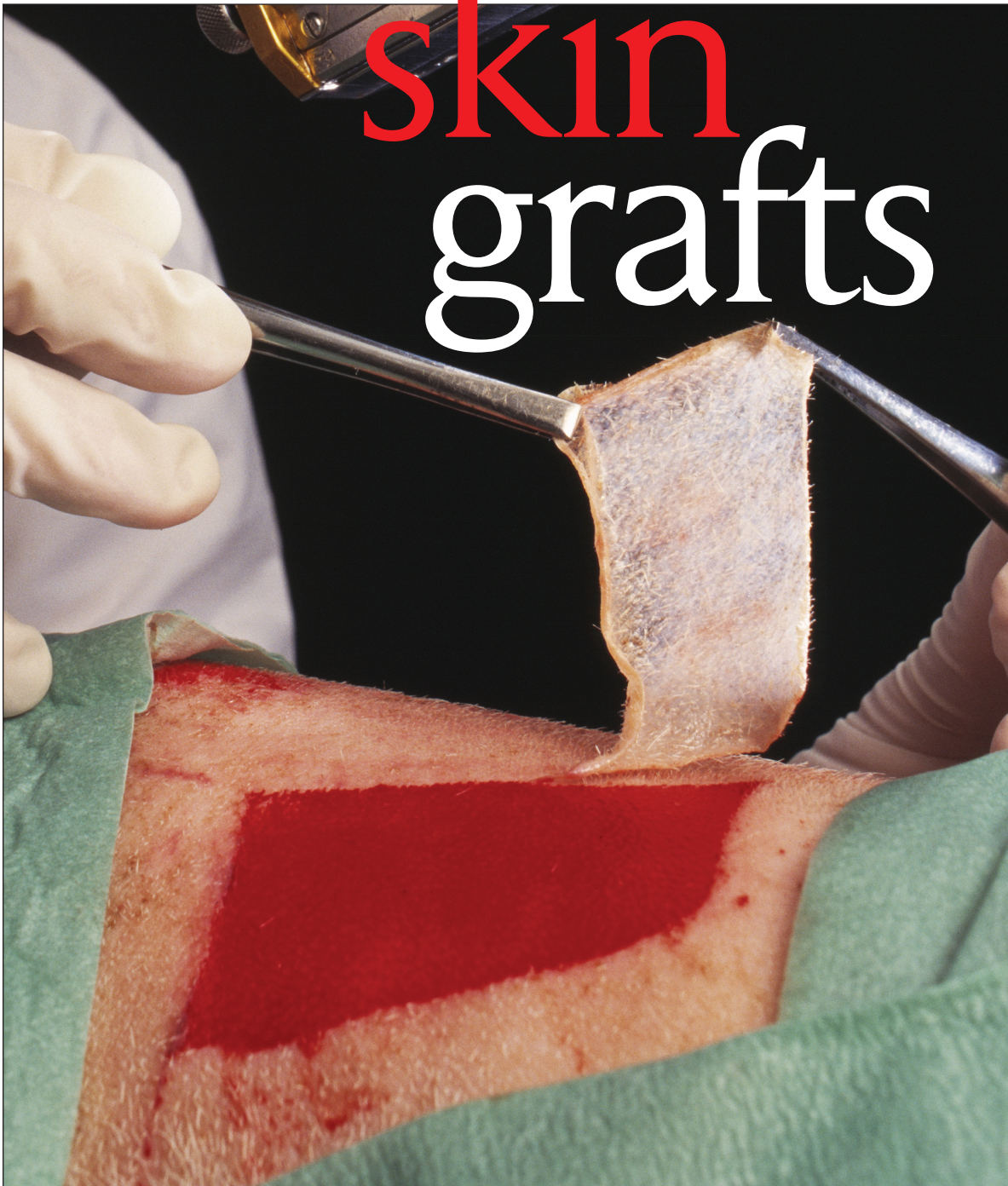




2.5
ANCC/AACN CONTACT HOURS

Enhance your
knowledge of

skin grafts



New advances in skin substitutes, dermal fillers, and other products have expanded the surgical approaches that can be considered to cover tissue defects.

Annette B. Wysocki, PhD, RN • Wanda A. Dorsett-Martin, DVM

Skin grafts are routinely used to close open skin defects that can't be primarily closed or to replace irreparably damaged skin. Restoration of the barrier and mechanical function of the skin protects against infection, offers pain relief, decreases evaporative fluid and heat loss, restores thermoregulation, and renews metabolic and sensory function.¹

Skin transplantation has been performed for over 2,500 years and was developed when nasal amputation was used as a form of punishment across Asia and Europe.²

The current general use of skin grafts dates from the mid to late 1800s.³ Data indicate that over 163,000 split-thickness and full-thickness skin grafts (FTSGs) are performed annually on Medicare recipients alone.⁴ At least 40,000 hospitalized burn victims and over 4 million individuals with chronic wounds are candidates for skin grafts.⁵ The majority of skin grafts are performed by plastic surgeons, followed by dermatologists, and general surgeons.⁴

Types of grafts

Skin grafts can be obtained from several sources, both human and animal. Skin grafts can include all or a portion of the skin including the epidermis and dermis. More recently, the use of skin substitutes, dermal fillers, and tissue expanders have increased surgeons' and dermatologists' ability to cover skin defects resulting from burns, traumatic injury, chronic wounds, or the excision of cancerous lesions. Skin grafting is the removal of skin from one part of the body, the donor site, and its placement on another part of the body, the recipient site. Grafts of any kind must acquire vascularization from the recipient bed to survive.^{6,7} Flaps differ from grafts in that a flap receives its blood supply

from a source other than the underlying bed on which it's placed via a pedicle or blood-carrying vessel.⁸ The major sources of skin grafts are autografts, homografts, and xenografts. Skin substitutes, dermal fillers, and tissue expanders provide additional dermal or epidermal components or both for wound coverage and to stimulate wound healing.

Autograft

Autografts refer to tissue transplanted from one location to another on the same individual. Autologous skin grafts are ideal because there's no risk of rejection due to incompatibility between donor and recipient. Autografts must be used to provide permanent coverage to replace allografts or xenografts, which provide only temporary coverage.

Allograft

Allografts or homografts refer to tissue transplanted between unrelated individuals of the same species. Allografts may be taken from another living donor, but most frequently are provided from cadaver skin.

Skin is strongly antigenic and subject to rejection.⁷ Allografts will vascularize or take, but will be rejected in about 10 days, unless the patient is immunosuppressed.⁶ Patients with major body burns are usually immunocompromised, leading to a delay in graft rejection.⁷ Successful allogeneic transplantation, or homografting, is only possible between identical twins who have the same genetic code and the immune system doesn't have to be suppressed.^{7,9}

Allografts promote vascular ingrowth and assist in preparing the wound bed for subsequent autografting. Successful allograft take usually indicates that an autograft will be successful.¹⁰

Xenograft

A xenograft, or heterologous skin graft, is tissue transplanted between different species. Although these grafts can be taken from several different animals, the pig has been the most widely used species. Xenografts are another source of temporary coverage and, like allografts, can stimulate the formation of granulation tissue to facilitate subsequent grafting.

A major disadvantage of xenografts is that the cellular components are susceptible to hyperacute rejection, which can occur from within minutes to hours after transplantation. Xenografting is rarely used in the United States, but is used in China where cultural beliefs limit the use of allograft.³ Bovine xenograft is used when cultural beliefs prohibit the use of porcine skin.

Skin substitutes

Skin substitutes were developed in part because of the limited availability of autologous skin in patients with large total body surface area burns and thereby have insufficient skin donor sites to provide adequate coverage. To provide a readily available source of coverage, various skin substitutes were developed, including epidermal, dermal, or composite materials using human, animal, or engineered materials or a combination to create partial or full-thickness skin constructs.

Cultured epithelial autografts were developed following the early pioneering work of Rhinewald and Green who first reported the ability to serially culture keratinocytes in 1975. This led to the development of epidermal replacement using autologous skin cells that are expanded in culture and then replanted onto the donor.³ The major advantage is the lack of rejection, but major disadvantages include fragile handling characteristics, the length of time required to expand the donor cells under culture conditions, and limited ability to expand the cells enough for use in large body burns.

Dermal substitutes are made from human or animal sources. They often incorporate synthetic support materials as well.³ The major advantages of these products are that they provide a thick, dermal substitute, are inexpensive and readily available, and have a prolonged shelf life and good handling characteristics. The major disadvantage is that they require at least one subsequent procedure to cover the dermal substitutes with viable epithelial cells at the wound site. Other concerns arise from the risk of disease

transmission and the ethics of for-profit companies using donated human skin tissue.

Composite skin substitutes have both an epidermis and dermis. There're two composite skin substitutes available on the market with living cells incorporated. The major advantage of these products is that they provide both an epidermis and dermis, and the immunogenic skin cells are removed to prevent graft rejection. The major disadvantages are that they're expensive, have a limited shelf life, are sometimes fragile to handle, and require logistical planning.

Another bilayered product available is made of gamma-irradiated human skin, which provides an extended shelf life, but doesn't have viable cells. Again, ethical concerns arise from the use of donated skin for commercial purposes.

Amniotic membranes have also been used to provide temporary wound coverage and are relatively easy to use and not prohibitively expensive. Some authors have reported that they are superior to allograft or xenograft^{11,12} but can be more fragile to handle and technically challenging to use.¹³ More recently, they've been used for persistent corneal epithelial defects¹⁴ and for other ocular injuries. The healing effect is due in part to the presence of amnion derived multipotent progenitor cells.

Dermal fillers, fibrin glues, tissue expanders

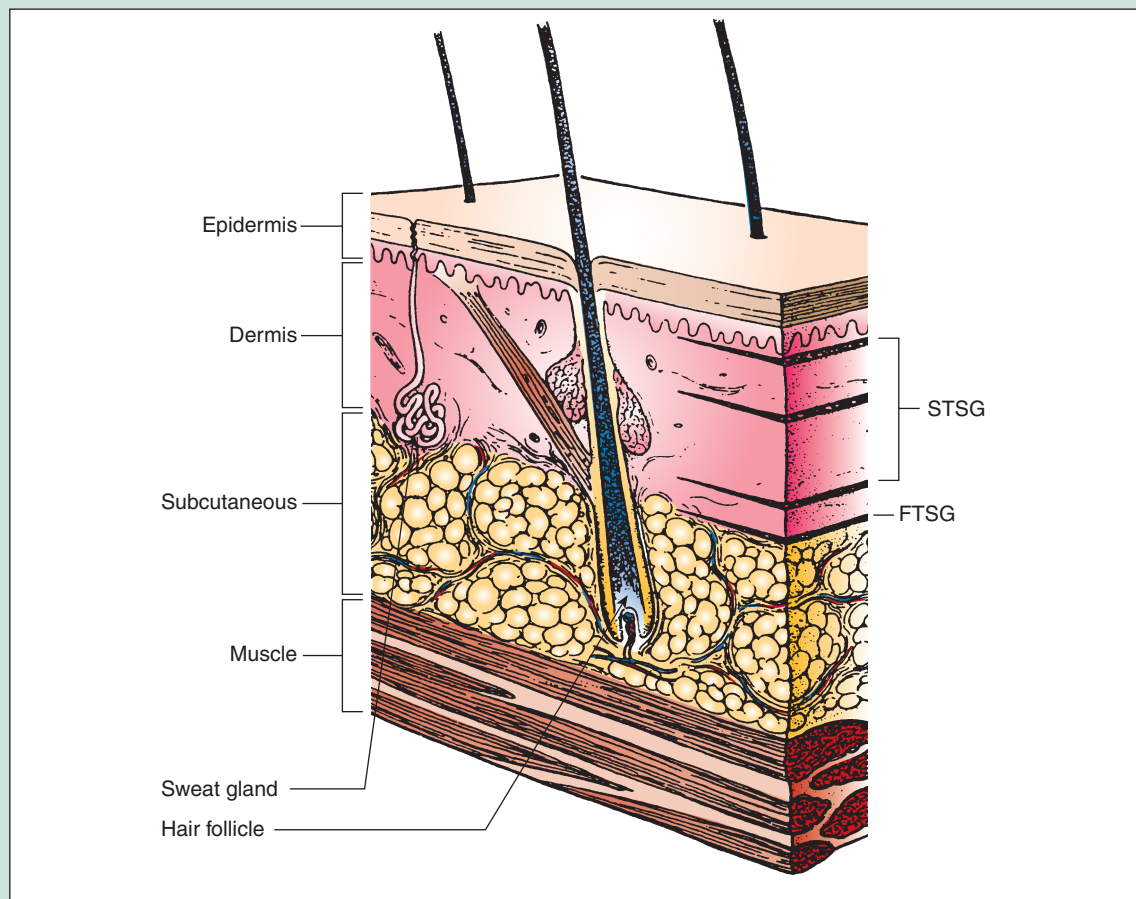
The use of dermal fillers, fibrin glues, and tissue expanders along with skin grafts have expanded the surgical approaches that can be considered to cover tissue defects. Dermal fillers are composed of collagen, hyaluronic acid, or calcium hydroxyl apatite. Fibrin glues supplied as fibrinogen, along with thrombin as a clotting agent, provide tissue bonding and hemostasis. New, enhanced versions are currently under development.¹⁵ Tissue expanders can be used to expand the skin, providing autologous skin for tissue reconstruction. Silicone balloon expanders are inserted to increase the skin surface area that can then be harvested to cover defects. This is especially advantageous when adjacent skin tissue can be expanded, providing a match for the color, thickness, skin architecture, and surface with the tissue needing replacement.

Classification

Skin has two major layers, the epidermis and dermis separated by a basement membrane zone. (See *Layers of the skin*.) The dermis, or inner layer,

Layers of the skin

See illustration below with the layers of the skin appropriate for STSG and FTSG.



Source: Smeltzer SC, Bare BG, Hinkle JL, Cheever, KH. *Brunner & Suddarth's Textbook of Medical-Surgical Nursing*. 11th ed. Philadelphia, Pa: Lippincott Williams & Wilkins, 2008; 1986.

is composed of fibroblasts embedded in a collagen matrix containing various skin appendages such as hair follicles, sweat, and sebaceous glands that can facilitate epidermal resurfacing if they're contained in the dermal portion removed from the donor site. The dermis also contains a blood supply, elastic fibers, free nerve endings, ground substance, and lymphatics.

The epidermis is the outer or top layer of the skin and is composed of actively dividing cells on top of a basement membrane that move upward and differentiate into surface cells, the stratum corneum, or squames, which are keratinocytes filled with keratin. The epidermis contains no blood supply¹; skin grafts can be harvested to include the epidermis and a portion of the dermis, called split-thickness skin grafts

(STSGs), or the epidermis and all of the dermis, called FTSGs.

STSGs

STSGs can be classified as thin (Thiersch-Ollier), ranging from 0.15 mm to 0.3 mm, medium or intermediate (Blair-Brown), ranging from 0.3 mm to 0.45 mm, or thick (Padgett), ranging from 0.45 mm to 0.6 mm. STSGs can be up to 4 inches wide and up to 10 to 12 inches long.^{9,15,16}

STSGs usually take or are more successful when they're thinner, but these are more prone to contraction. Intermediate or thick STSGs are less prone to contraction.¹⁶ STSGs can be meshed to expand up to nine times their size to provide more extensive coverage, which is especially helpful in large body burns.¹⁷

Generally, mesh grafts are expanded by 1:1.5, 1:2, or 1:3 so that they can cover 1.5 to 3 times the surface area of an unmeshed graft. However, this may produce a less-than-ideal cosmetic result with a pebbly or cobblestone appearance compared with unmeshed or sheet grafts. The advantage of meshing the graft is that it allows exudates and blood to flow through the interstices rather than collect as a pocket of fluid beneath the graft, which can prevent graft take. Meshed grafts also conform better to irregular wound beds. One of the major advantages of STSGs is that the donor site can be reharvested once healing is complete and the STSGs are more easily vascularized.^{7,10} Disadvantages of STSGs are that they become hypopigmented or hyperpigmented, and have decreased thickness, which limits their use over areas where a substantial dermal component is required.^{7,10}

Another version of the meshed graft is the Meek graft, created when the STSG is cut into smaller squares and then applied to the open wound defect. The smaller squares are placed on a pre-folded nylon sheet, which is then expanded thereby increasing the size of the graft. Meek grafts have the advantages of the meshed graft and yield a better cosmetic result. However, the disadvantage of this approach is the time and technical skill necessary to create, use, and handle the graft.¹⁸

FTSGs

FTSGs (Wolfe-Krause) are generally larger than 0.6 mm in thickness. However, depth can vary depending on body location. Total skin thickness ranges from about 0.5 mm for the tympanic membrane to 6 mm on the soles of the feet and palms.¹ FTSGs contain many dermal appendages from the site where they are harvested. FTSGs are usually only taken if the graft is small, as it has greater metabolic requirements and more extensive angiogenesis is required.¹⁶

These grafts provide the best elasticity with minimal contraction. FTSGs offer superior cosmetic results, but have less reliable graft survival.⁷ They offer better protection, are more resilient, and establish better sensibility.¹⁶ These grafts are especially useful in areas prone to shear and load stress such as palms, soles, and areas over joints.¹⁰

Pinch grafts

Pinch grafts are irregular, small, cone-shaped sections of tissue harvested when the skin is pinched up and then excised from the base with scissors or scalpel. Thus, the thickness can vary depending on the area pinched. Pinch grafts are more commonly used by dermatologists or primary care practitioners and can be performed in an office setting. They have been used to cover open venous leg ulcers, but this requires multiple pinch grafts.

The advantage of pinch grafts is that they can be readily obtained and transplanted during an office visit. Disadvantages are that the final cosmetic result can have a pebbly appearance and a successful closure may require multiple attempts.

Physiology and pathophysiology

Successful skin grafting depends on antigenic compatibility, an adequate vascular supply in the recipient wound bed, the presence of viable granulation tissue, local oxygenation, bacterial counts below 10^5 per gram of tissue, and the ability of the graft to adhere to the recipient wound bed.⁶

The process of graft take begins with an initial period of imbibition or plasmatic imbibition with the absorption of nutrients

from plasma in the recipient wound bed that mirrors the inflammatory phase in the first 24 to 48 hours and a revascularization phase that lasts about 2 to 3 days for STSGs and up to 5 to 7 days for FTSGs. This is subsequently followed by an adjustment and retraction phase and distension mediated in part by myofibroblasts.⁹ Skin grafts can be compromised if there're excessive exudates or blood that hinder the graft's ability to adhere to the wound bed.

Initially, fibrin from the debrided recipient site provides graft adherence, which is then gradually revascularized as new capillary endothelial cells bud and migrate into the graft. An ingrowth of a vascular network, or inosculation, is established by the fourth day in which there's direct anastomosis of the vessels of the recipient wound bed with those of the graft.^{6,15} Once graft take occurs, there's a period of retraction during which fibroblasts remodel the new skin patch. After 1 to 2 months, distension occurs and the graft knits into the surrounding skin tissue. Reinnervation and modification of pigmentation also occur at this time. Reinnervation begins at the edges, moving in to

Autologous skin grafts are ideal because there's no risk of rejection due to incompatibility between donor and recipient.

the center of the graft and is never restored to the level of the uninjured tissue, especially in STSGs.¹⁷

Clinically, the new graft appears pale and white, but as revascularization occurs it becomes pinkish, thus firmly establishing adherence to the recipient wound bed.⁹ Underlying pathologies such as diabetes, infection, necrotic and adipose tissue, exposed bone, cartilage, nerves or tendons, arthritis, or vasculopathies can prevent or inhibit graft take. Grafting is generally not recommended over exposed bone, nerves, or tendons unless as a temporary or emergency measure.¹⁶

Allografts or homografts and heterografts can be used fresh or preserved, however, preserved allografts or heterografts are less antigenic after being subjected to processing and are more commonly used today. Fresh homografts or heterografts begin the same process of inhibition but are usually rejected by the 6th or 7th day, although the time can vary depending on the immunocompetence of the recipient and the antigenicity of the donor tissue.

Patients with immunosuppressed burns can extend graft rejection by up to 10 to 14 days.¹⁹ Rejection is usually heralded by the edematous graft in which a dermoepidermal phlycten or blister forms resulting in the desquamation of the epidermis that detaches from the dermis.⁹ The Langerhans cell, an antigen-presenting cell in the epidermis, is involved in the rejection of the donor graft. Graft rejection is mediated by activation of T cells when Langerhans cells migrate to the lymph nodes of the recipient leading to T-cell activation and destruction of the major histocompatibility complex-incompatible cells.¹⁹ Rejection of dermis follows later as the dermis has less antigenicity compared with epidermis.

Rejection of heterografts or xenografts can occur much faster and can sometimes be accompanied by an anaphylactic reaction of the recipient. In these situations, the graft is removed immediately or on the second or third day if the reaction is delayed.

Graft storage and preservation techniques involve freezing using liquid nitrogen and glycerolization. Cryopreservation of donor skin maintains its vitality and improves the take due to reduced antigenicity resulting from the liquid nitrogen's extreme temperature.

Cryopreserved skin can be stored up to 5 years and donor tissue is screened before use in accordance with the American Association of Tissue Banks

guidelines.²⁰ Cryopreserved skin is provided by a network of tissue banks across the United States. Glycerolization of skin results in devitalized tissue that acts as a biological dressing, and glycerol treatment is antibacterial and virucidal.^{9,19}

Skin graft donor sites usually heal uneventfully by the dermal fibroblasts and epithelial cells along the edges and from epithelial cells found in the skin appendages, hair follicles, sweat, and sebaceous glands.^{6,16} Healing begins as soon as the graft is removed when degranulating blood cells deposit a fibrin/fibronectin provisional matrix along with growth factors such as transforming growth factor beta, platelet-derived growth factor, and fibroblast growth factor. The time to heal depends on the

size and depth of the STSG and the number of skin appendages remaining in the dermal component. In general, thicker STSGs take longer to heal and the greater the number of dermal

appendages, the shorter the time to heal.¹⁷ A thin STSG donor harvest site generally heals within 7 days.⁶ In comparison, a full-thickness skin graft donor site takes about 2 to 3 weeks to heal.

Preoperative considerations

Preoperatively, the patient, graft donor site, and the recipient wound must be evaluated by the nurse and operating physician. Patients should also be checked for anticoagulant use and allergies, along with the usual preoperative evaluation. The recipient wound bed is evaluated to ensure that it's not clinically infected and that the granulation tissue is healthy with little or no necrotic tissue.

Graft donor sites are usually selected to match the tissue requiring replacement and to provide the best cosmetic or functional outcome.^{6,21} However, in burn injuries, site selection can be limited and restricted to the areas where skin remains intact. The most suitable areas for STSG are the gluteal region, anterior, lateral, or posterior thigh, medial thigh, abdomen, and sometimes the upper limbs.^{9,10} In elective procedures, areas that can be covered with clothing are considered first. Other site selection factors are hair distribution, skin color, and thickness.^{6,21} STSGs are used when cosmetic result isn't the primary focus, especially when they are meshed; these are more commonly used in burn injury or trophic ulcers.

FTSGs provide superior cosmetic results, but have less reliable graft survival.

FTSG donor sites are selected to reduce the resulting scar while producing the best compatibility for the recipient site. FTSGs are usually taken from areas where there's skin extensibility to minimize scarring and are closed primarily or in rare cases with a STSG¹⁷ so that the resulting edges can be primarily sutured.⁶ Other factors important for donor site selection include the ease of access, ability to manage the resulting wound and scar, and healing capacity of the donor site.¹⁶

Intraoperative considerations

Harvesting skin grafts is always instrument-dependent and operator-dependent. Before harvesting, the donor site is prepped in a sterile fashion. A local anesthetic agent with or without epinephrine may also be used. The recipient site is measured and the donor site can be marked to ensure that the appropriate sized skin graft is harvested.²² The harvested skin graft is usually larger than the size of the wound defect, as the STSG undergoes a limited amount of contraction or shrinkage following harvest. STSGs and FTSGs are harvested operatively and can be obtained using a free hand or powered dermatome.^{9,17,23} Free hand knives such as scalpel blades, double-edged razor blades, Weck blades, Humby knives, or Blair knives can be used but require a high level of technical skill to avoid uneven graft thickness or ragged edges.¹⁷

Powered dermatomes are more commonly used because they offer greater uniformity in harvesting STSGs, although the technical skill of the operator is still a major factor in obtaining a uniform skin thickness. Powered dermatomes include manual, electric, or air-powered models. Dermatome use requires proper orientation of the blade, placement of the width guard, and proper depth setting before skin harvesting.¹⁷

Harvesting skin for an STSG from the donor site is facilitated by applying mineral oil over the skin using tongue blades.²² In addition, mineral oil is also applied as a thin layer over the dermatome blade to further assist in reducing friction and ensures a more uniform donor skin thickness. Tongue blades are then used to apply pressure to the donor skin site as the skin tissue is harvested to flatten the surface and enhance skin removal. Generally, the dermatome is positioned at

about a 45-degree angle and is moved downward until skin contact is made. Using steady, equal pressure, the blade is passed along a parallel plane until the desired length of tissue is obtained, at which time the dermatome is angled upward to terminate skin removal. The donor site exsanguinates due to the transected dermal blood supply and can then be covered with an impregnated gauze dressing or a non-gauze dressing such as a hydrocolloid, semi-occlusive, foam, or antimicrobial dressing with silver.¹⁵

Once the skin tissue is removed, it can then be transferred to the recipient site or meshed. Skin for meshing is usually transferred to the dermal side to maintain the orientation and prevent confusion when using a skin graft carrier.²² Once removed, the STSG will curl toward the dermis. The dermal carrier used to mesh the skin should be ridged side up and the skin should be spread out with no curled edges or bubbles. The skin is prepped with 0.9% sodium chloride solution and placed in the

mesher. As the skin is processed through the mesher, it should be supported and moved away to prevent shredding.²²

FTSGs are usually small and can be removed using a scalpel from the inguinal, antecubital space, and axillary folds. Before

use in the open wound or other defect, the fat must be removed to insure graft take.

The recipient site or wound is usually debrided with a scalpel and round fibrotic edges that may contain apoptotic cells are removed or refreshed.²¹ Some surgeons flush the granulating wound bed with jet lavage or other instruments using 0.9% sodium chloride solution in an attempt to remove colonizing bacteria. Other surgeons use solutions containing antibiotics such as bacitracin or polymyxin.

Hemostasis of bleeding vessels is achieved by cauterizing or clamping to prevent hematoma formation, which can disrupt the graft.²² However, cauterization should be avoided because the resulting thermal tissue damage can impede subsequent graft take. Topical or injected epinephrine is sometimes employed to limit bleeding and isn't known to compromise graft survival.¹⁷

Once the recipient site is ready, the skin graft is positioned over the wound bed and can be stapled, sutured, or steri-stripped in place.^{15,16} A stent or bolster dressing is then used to provide adequate

Hemostasis of bleeding vessels is achieved by cauterizing or clamping to prevent hematoma formation, which can disrupt the graft.

pressure to hold the graft in place and insure contact with the wound to maximize graft take but without occluding capillary circulation that would prevent imbibition of the graft itself.^{6,15,21,23,24} These dressings can be constructed by placing saline moistened gauze or cotton balls in a large piece of a petrolatum impregnated dressing and folding the impregnated gauze over so that it provides a nonadherent contact with the skin graft, but is held in place with long sutures that're tied over the stent or bolster. If deemed necessary, this dressing is then further supported or reinforced with an abdominal (ABD) pad and then secured in place with roller gauze or coban.

Splints can also be used depending on the location and are typically used over a mobile surface or joint. This dressing usually remains in place for about a week unless symptoms of an infection occur such as pain, fever, or bleeding.¹⁶ Vacuum-assisted closure is also an option, but an impregnated gauze dressing must be used between the graft and sponge to prevent problems with graft take when removing the sponge.¹⁵

Postoperative considerations

Postoperatively, patients are sometimes kept in the hospital for 23 hours after skin grafting is performed to be sure that the graft is adequately secured in place and that the patient's mobility is limited to prevent shearing forces over the graft site that could dislodge the skin graft.

Patients are instructed by the nurse to guard the recipient site judiciously and if it's over a leg or an arm, a physical therapist can be consulted to assist the patient with crutches or a walker, if necessary. If the patient is discharged, a nurse can check the recipient and donor site at the next return visit to the office or clinic or a home health nurse can assess the graft recipient and donor site in about 3 days to be sure that circulation is adequate and that there're no signs of complications. If the patient is in the hospital for a prolonged period, such as a burn patient, then both the recipient and the donor site can be monitored for complications.

The graft recipient site is carefully checked to be sure that there's no excessive serous or serosanguinous fluid collecting under the skin graft. If this occurs, the skin graft can be nicked with a No. 11 blade or incised to permit the pocket of fluid to

escape and by rolling a cotton-tipped applicator over the graft to express the pocket of fluid. This will improve the graft's ability to take.^{6,16} If meshed grafts are used, the interstices of the meshed skin practically eliminate this problem. Leeches, *Hirudo medicinalis*, have also been used to salvage grafts threatened by venous congestion.¹⁰

The skin graft donor site is also monitored for healing during this time. Although many surgeons continue to use an impregnated gauze dressing, these can be more painful than newer dressing products such as foam dressing. If an impregnated gauze dressing is used, the edges are trimmed away once hemostasis is achieved and the coagulum provides adherence to the graft donor site followed by drying when left open to air. Patients commonly find the graft donor site more painful than the recipient site.¹⁶ Over time, the edges of the gauze are trimmed and with restoration of dermal and epidermal layers, the dressing self-releases from the donor site.

At the first dressing change, the bandages should be removed with care to prevent disruption of the newly adhered graft. It may be necessary to use saline solution to moisten the dressing. Nurses experienced in the removal of a bolster or tie-over dressing are key to maintaining graft adherence, especially at the first dressing change when the adherence can be somewhat tenuous.

Some practitioners may opt to use hydrogen peroxide to loosen any adherent part of the dressing, especially if 0.9% sodium chloride solution doesn't safely accomplish dressing

removal. However, hydrogen peroxide is cytotoxic and contact with the graft can destroy dermal fibroblasts and basal keratinocytes. Observe the graft recipient site for odor, drainage, and color. Examine the surrounding tissue and edges for maceration that may lead to graft adherence failure. Look for any additional signs of infection and report graft failure to the operating surgeon or dermatologist.

Once the dressing is removed, gently cleanse the recipient graft donor site and reapply an impregnated or nonadhesive dressing. Cover this with a secondary dressing secured in place with coban. If a splint was used, it may need to be reapplied as well. At this stage, the graft still needs to be protected from excessive pressure and shearing forces that can lead to

● ● ●
Postoperatively, patients are sometimes kept in the hospital for 23 hours after skin grafting is performed to be sure that the graft is adequately secured in place.
● ● ●



removal. The second dressing is usually left in place for another 5 to 7 days. **OR**

REFERENCES

1. Wysocki AB. Anatomy and physiology of skin and soft tissue. In: Bryant RA, Nix DP, eds. *Acute and Chronic Wounds: Current Management Concepts*. 3rd edition. Philadelphia, Pa: Mosby/Elsevier; 2007:39-55.
2. Ang GC. History of skin transplantation. *Clin Dermatol*. 2005;23(4):320-324.
3. Burd A, Chiu T. Allogenic skin in the treatment of burns. *Clin Dermatol*. 2005;23(4):376-387.
4. Shaffer CL, Feldman SR, Fleischer AB, et al. The cutaneous surgery experience of multiple specialties in the Medicare population. *J Am Acad Dermatol*. 2005;52(6):1045-1048.
5. American Burn Association. Burn Incidence and Treatment in the US: 2007 Fact Sheet. Available at: http://www.ameriburn.org/resources_fact_sheet.php. Accessed July 28, 2008.
6. Thorne CH. Techniques and principles in plastic surgery. In: Thorne CH, ed. *Grabb and Smith's Plastic Surgery*. 6th edition. Philadelphia, Pa: Lippincott Williams and Wilkins; 2007:3-14.
7. Lee WP, Feili-Hariri M, Butler PE. Transplant biology and applications to plastic surgery. In: Thorne CH, ed. *Grabb and Smith's Plastic Surgery*. 6th edition. Philadelphia, Pa: Lippincott Williams and Wilkins; 2007:52-57.
8. Jones NF, Lister GD. Free skin and composite flaps. In: Green DP, Hotchkiss RN, Pederson WC, et al., eds. *Green's Operative Hand Surgery*. 5th edition. Philadelphia, Pa: Elsevier/Churchill Livingstone; 2005:1715-1755.
9. Andreassi A, Bilenchi R, Biagioli M, et al. Classification and pathophysiology of skin grafts. *Clin Dermatol*. 2005;23(4):332-337.
10. Vedder NB, Hanel DP. The mangled upper extremity. In: Green DP, Hotchkiss RN, Pederson WC, et al., eds. *Green's Operative Hand Surgery*. 5th edition. Philadelphia, Pa: Elsevier/Churchill Livingstone; 2005:1587-1628.
11. Mermet I, Pottier N, Sainthillier JM, et al. Use of amniotic membrane transplantation in the treatment of venous leg ulcers. *Wound Repair Regen*. 2007;15(4):459-464.
12. Gruss JS, Jirsch DW. Human amniotic membrane: a versatile wound dressing. *Can Med Assoc J*. 1978;118(10):1237-1246.
13. Atiyeh BS, Hayek SN, Gunn SW. New technologies for burn wound closure and healing -Review of the literature. *Burns*. 2005;31(8):944-956.
14. Seitz B, Das S, Sauer R, et al. Amniotic membrane transplantation for persistent corneal epithelial defects in eyes after penetrating keratoplasty. *Eye*. 2008; [Epub ahead of print].
15. Klein MB. Thermal, chemical, and electrical injuries. In: Thorne CH, ed. *Grabb and Smith's Plastic Surgery*. 6th edition. Philadelphia, Pa: Lippincott Williams and Wilkins; 2007:132-149.
16. Browne EZ, Pederson WC. Skin grafts and skin flaps. In: Green DP, Hotchkiss RN, Pederson WC, et al., eds. *Green's Operative Hand Surgery*. 5th edition. Philadelphia, Pa: Elsevier/Churchill Livingstone; 2005:1629-1648.
17. Revis Jr., DR, Seagle MB. Skin Grafts. *EMedicine*. Available at: <http://www.emedicine.com/plastic/TOPI392.HTM>. Accessed July 28, 2008.
18. Hierner R, Degreef H, Vranckx JJ, et al. Skin grafting and wound healing - the "dermatoplastic team approach." *Clin Dermatol*. 2005; 23(4): 343-352.
19. Richters CD, Hoekstra MJ, du Pont JS, et al. Immunology of skin transplantation. *Clin Dermatol*. 2005;23(4):338-342.
20. Ben-Bassat H. Performance and safety of skin allografts. *Clin Dermatol*. 2005;23(4):365-375.
21. Ogawa R, Hyakusoku H, Ono S. Useful tips for successful skin grafting. *J Nippon Med Sch*. 2007; 74(6):386-392.
22. Snyder RJ, Doyle H, Delbridge T. Applying split-thickness skin grafts: A step-by-step clinical guide and nursing implications. *Ostomy Wound Manage*. 2001;47(11):20-26.
23. Grande D, Mezebish DS. Skin grafting. *EMedicine*. Available at: <http://emedicine.com/derm/topic867.htm>. Accessed July 28, 2008.
24. National Institutes of Health. Skin Graft. MedlinePlus Medical Encyclopedia. Available at: www.nlm.nih.gov/medlineplus/ency/article/002982.htm. Accessed July 28, 2008.

At the University of Mississippi (Jackson) Medical Center, Department of Surgery, Division of Plastic Surgery, Dr. Annette B. Wysocki is a professor at the School of Nursing and Medicine and Dr. Wanda A. Dorsett-Martin is an assistant professor of Surgery Research at the School of Medicine.

The authors have disclosed that they have no financial interest related to this article.



Go to <http://www.nursingcenter.com/CE/ORnurse> and receive a certificate *within minutes*.

INSTRUCTIONS

Enhance your knowledge of skin grafts

TEST INSTRUCTIONS

- To take the test online, go to our secure Web site at <http://www.nursingcenter.com/ORnurse>.
- On the print form, record your answers in the test answer section of the CE enrollment form on page 39. Each question has only one correct answer. You may make copies of these forms.
- Complete the registration information and course evaluation. Mail the completed form and registration fee of \$24.95 to: **Lippincott Williams & Wilkins, CE Group**, 2710 Yorktowne Blvd., Brick, NJ 08723. We will mail your certificate in 4 to 6 weeks. For faster service, include a fax number and we will fax your certificate within 2 business days of receiving your enrollment form.
- You will receive your CE certificate of earned contact hours and an answer key to review your results. There is no minimum passing grade.
- Registration deadline is October 31, 2010.

DISCOUNTS and CUSTOMER SERVICE

- Send two or more tests in any nursing journal published by Lippincott Williams & Wilkins together and deduct \$0.95 from the price of each test.
- We also offer CE accounts for hospitals and other health care facilities on nursingcenter.com. Call 1-800-787-8985 for details.

PROVIDER ACCREDITATION

Lippincott Williams & Wilkins, publisher of *OR Nurse 2008* journal, will award 2.5 contact hours for this continuing nursing education activity.

Lippincott Williams & Wilkins is accredited as a provider of continuing nursing education by the American Nurses Credentialing Center's Commission on Accreditation.

Lippincott Williams & Wilkins is also an approved provider of continuing nursing education by the American Association of Critical-Care Nurses #00012278 (CERP category A), District of Columbia, Florida #FBN2454, and Iowa #75. LWW home study activities are classified for Texas nursing continuing education requirements as Type 1. This activity is also provider approved by the California Board of Registered Nursing, Provider Number CEP 11749 for 2.5 contact hours.

Your certificate is valid in all states.